

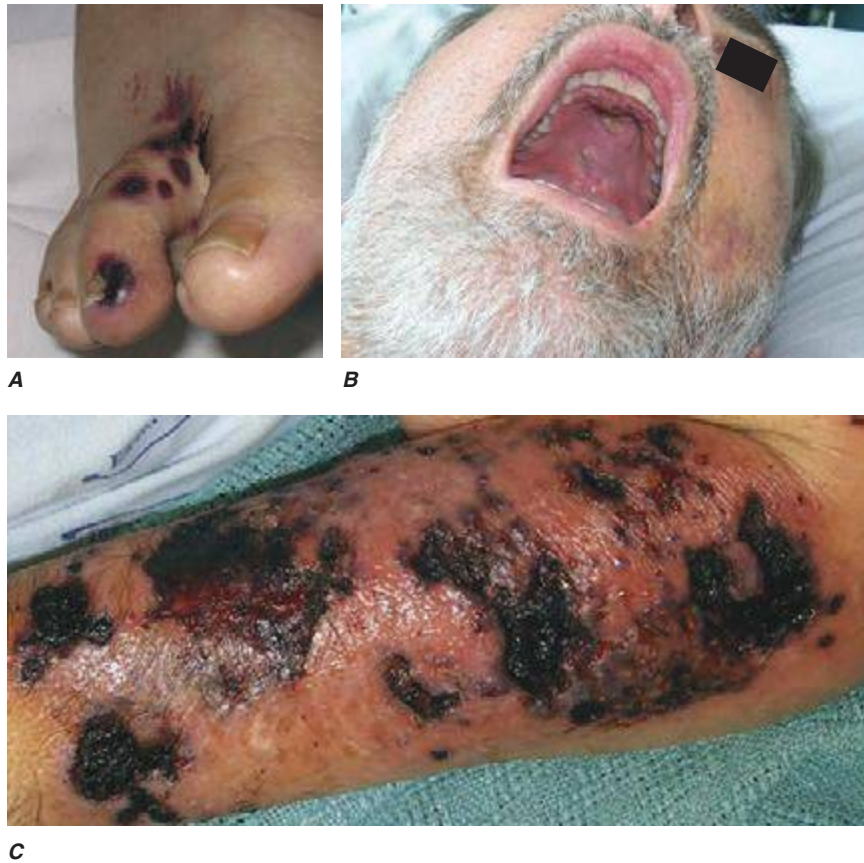

FIGURE 76e-55 Skin lesions of neutropenic patients. **A.** Hemorrhagic papules on the foot of a patient undergoing treatment for multiple myeloma. Biopsy and culture demonstrated *Aspergillus* species. **B.** Eroded nodule on the hard palate of a patient undergoing chemotherapy. Biopsy and culture demonstrated *Mucor* species. **C.** Ecthyma gangrenosum in a neutropenic patient with *Pseudomonas aeruginosa* bacteremia.

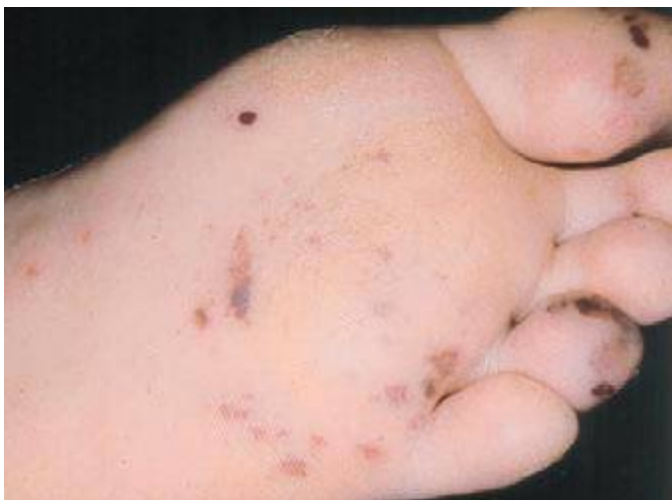

FIGURE 76e-56 Septic emboli, with hemorrhage and infarction due to acute *Staphylococcus aureus* endocarditis. (Courtesy of L. Baden, MD; with permission.)

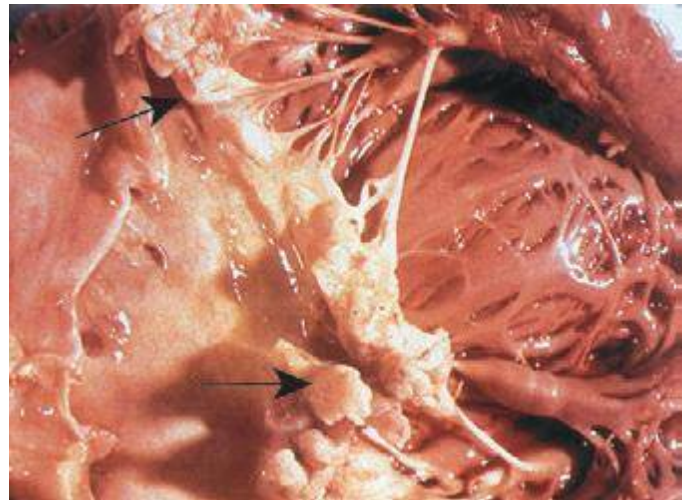


FIGURE 76e-57 Vegetations (arrows) due to viridans streptococcal endocarditis involving the mitral valve. (Courtesy of AW Karchmer, MD; with permission.)