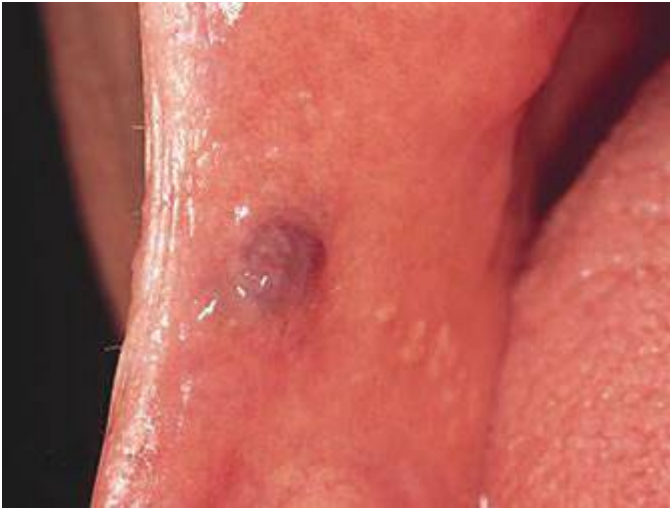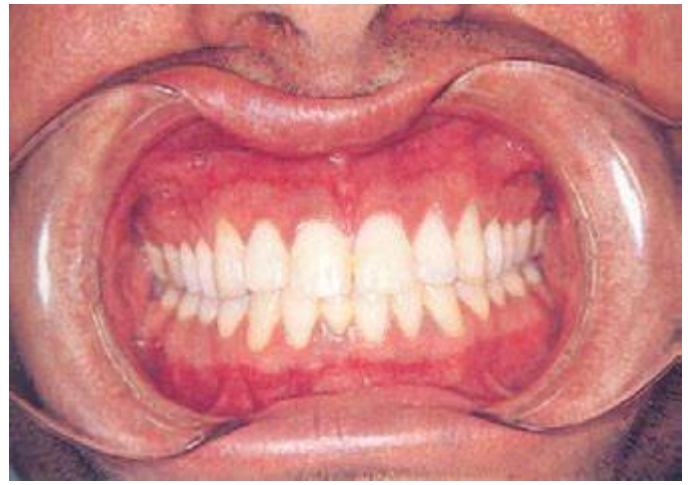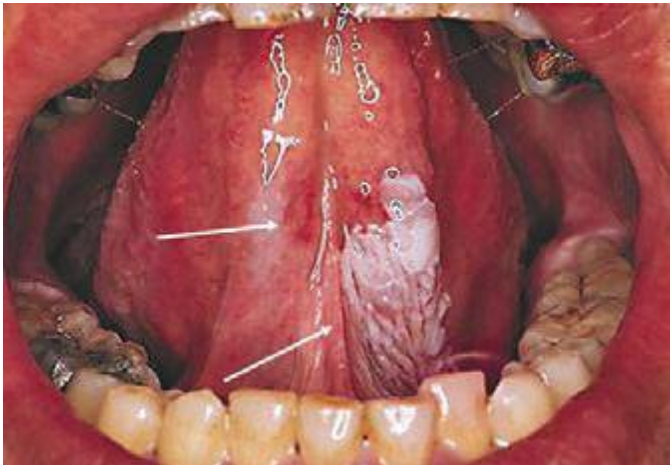


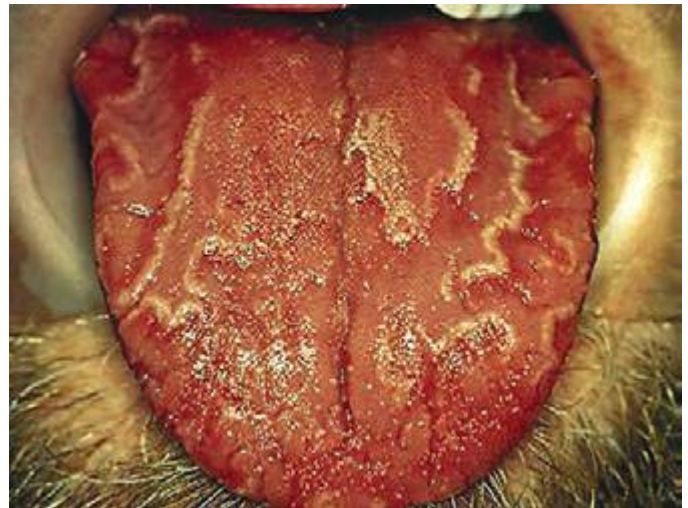**FIGURE 46e-10** Traumatic lesion inside of cheek.



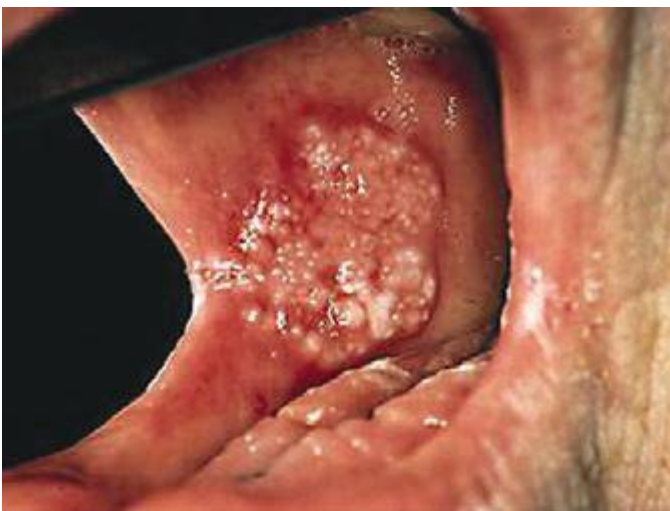**FIGURE 46e-13** Healthy mouth.



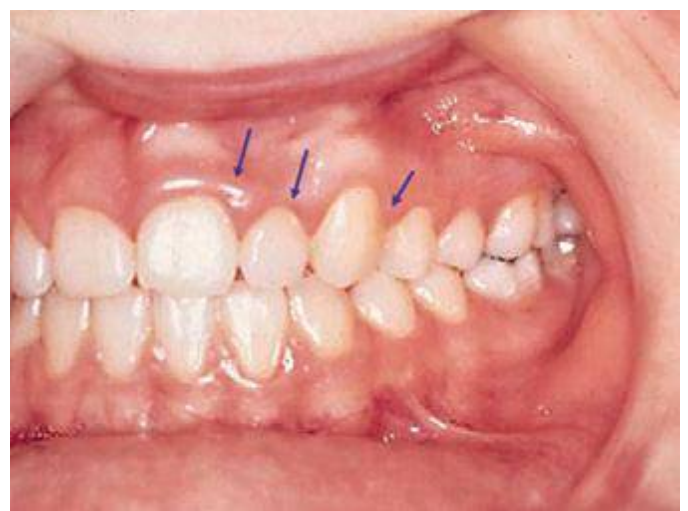
**FIGURE 46e-11** Oral leukoplakia, subtype homogenous leukoplakia.



**FIGURE 46e-14** Geographic tongue.



**FIGURE 46e-12** Oral carcinoma.



**FIGURE 46e-15** Moderate gingivitis.