

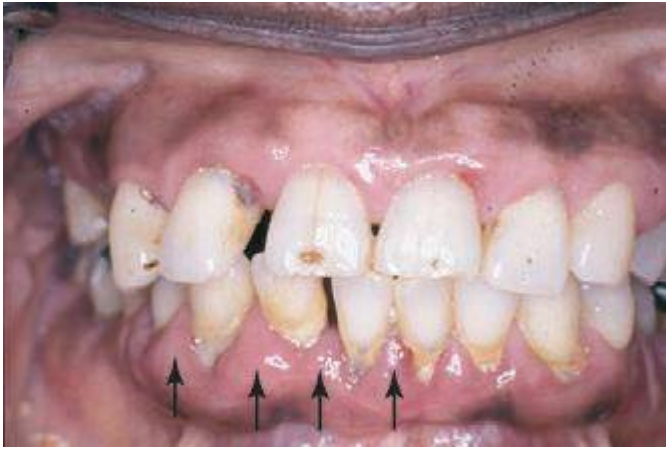

FIGURE 46e-6 Severe periodontitis.

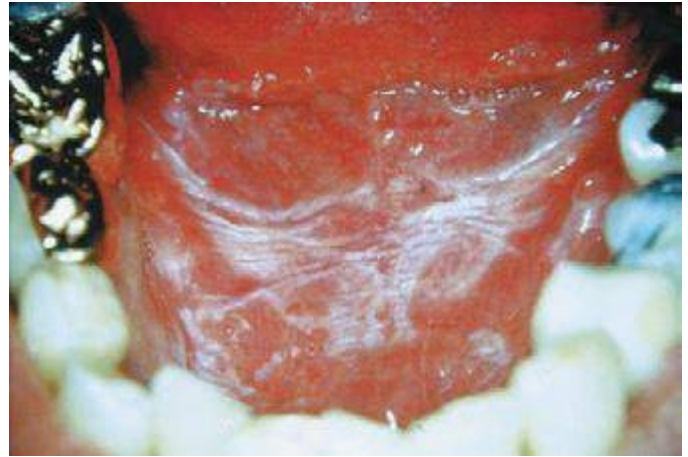

FIGURE 46e-8 Sublingual leukoplakia.

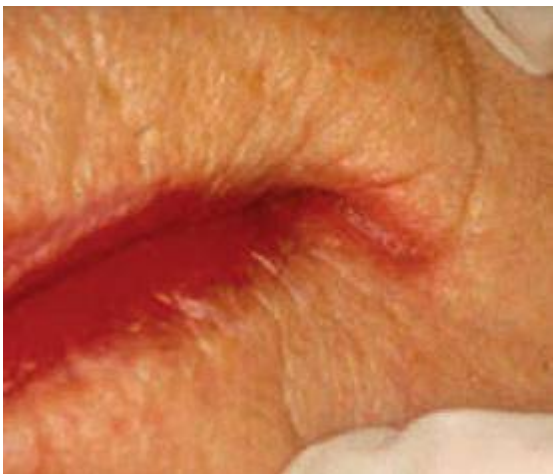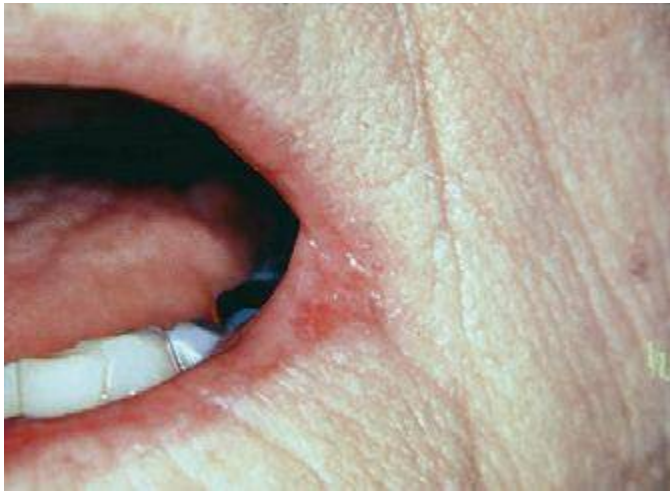

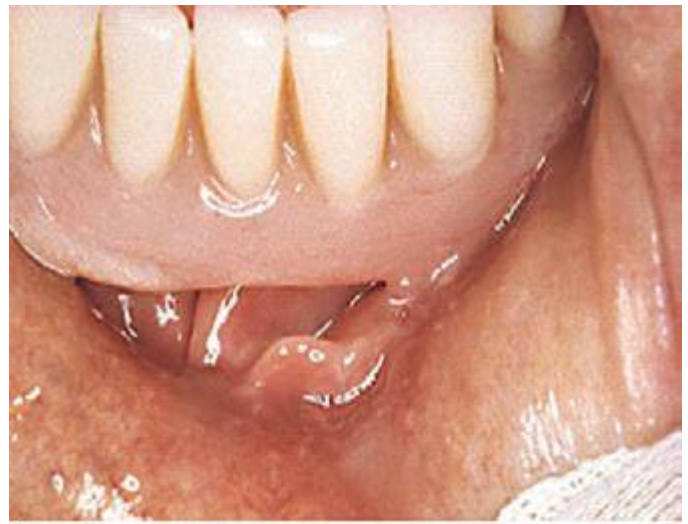
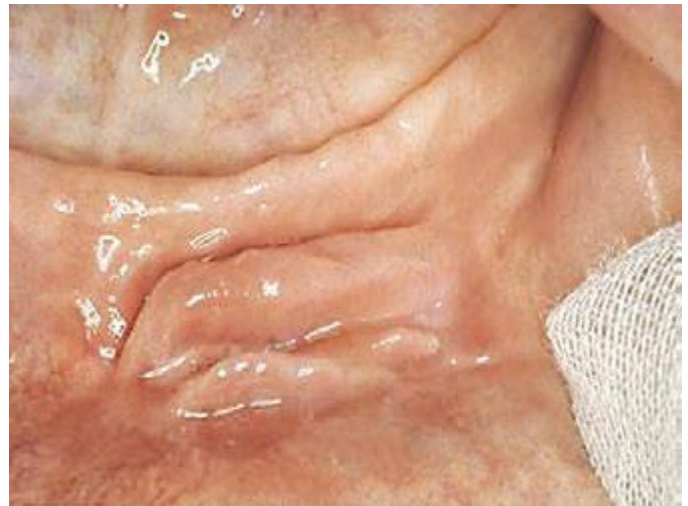FIGURE 46e-7 Angular cheilitis.



A



B

FIGURE 46e-9 **A.** Epulis (gingival hypertrophy) under denture. **B.** Epulis fissuratum.