

The health status of the oral cavity is linked to cardiovascular disease, diabetes, and other systemic illnesses. Thus, examining the oral cavity for signs of disease is a key part of the physical exam. This chapter presents numerous outstanding clinical photographs illustrating many of the conditions discussed in [Chap. 45](#), Oral Manifestations of Disease. Conditions affecting the teeth, periodontal tissues, and oral mucosa are all represented.

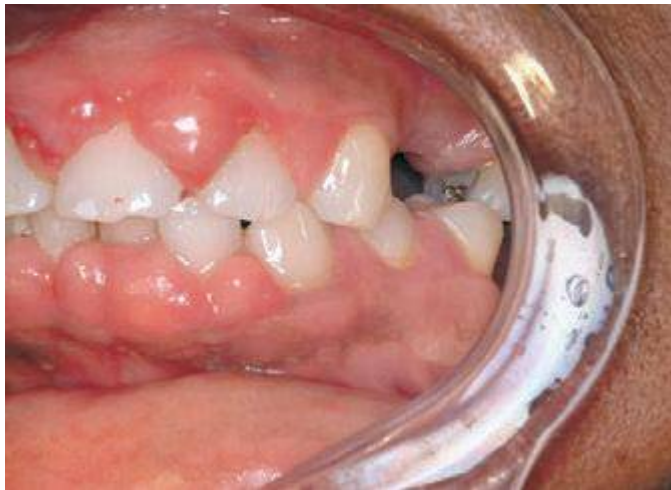

FIGURE 46e-1 Gingival overgrowth secondary to calcium channel blocker use.

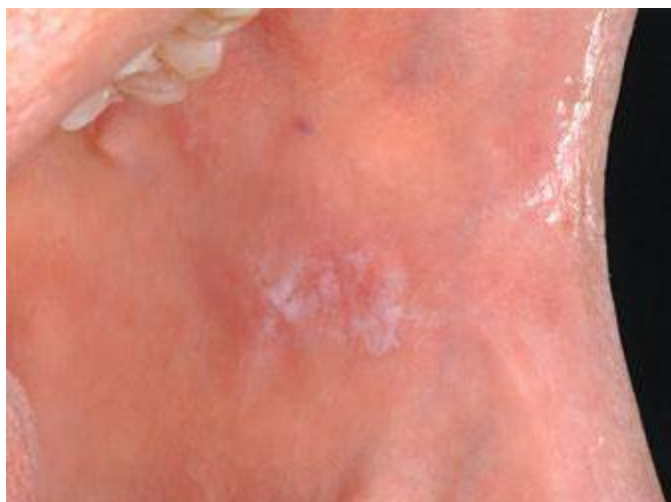

FIGURE 46e-2 Oral lichen planus.

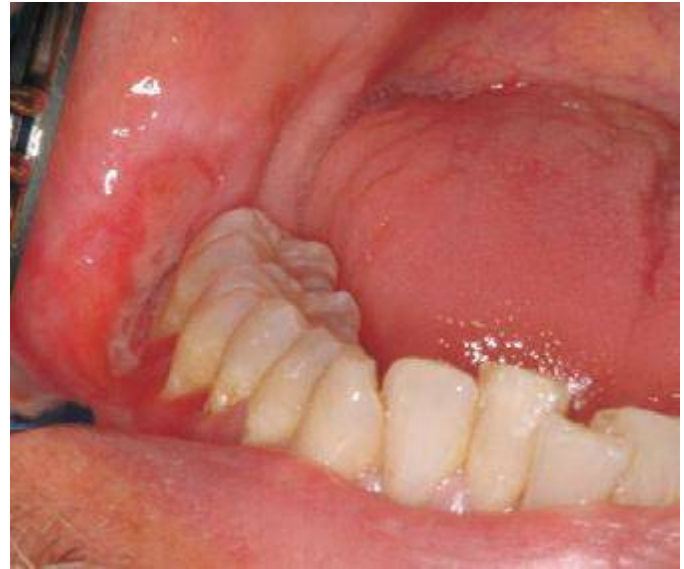

FIGURE 46e-3 Erosive lichen planus.

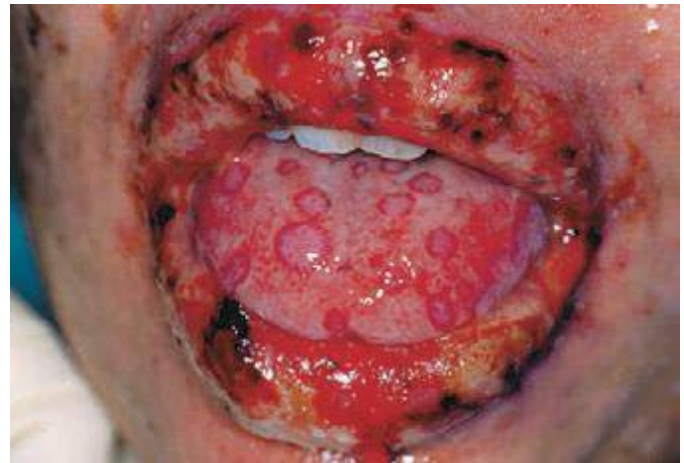

FIGURE 46e-4 Stevens-Johnson syndrome—reaction to nevirapine.

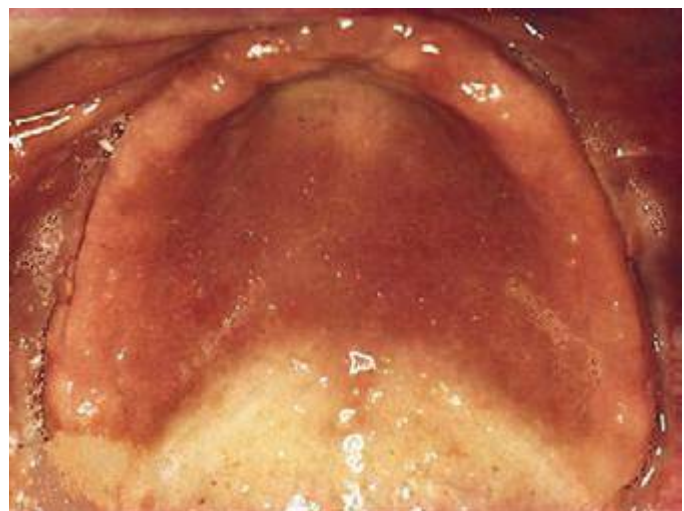


FIGURE 46e-5 Erythematous candidiasis under a denture (i.e., the patient should be treated for this fungal infection).