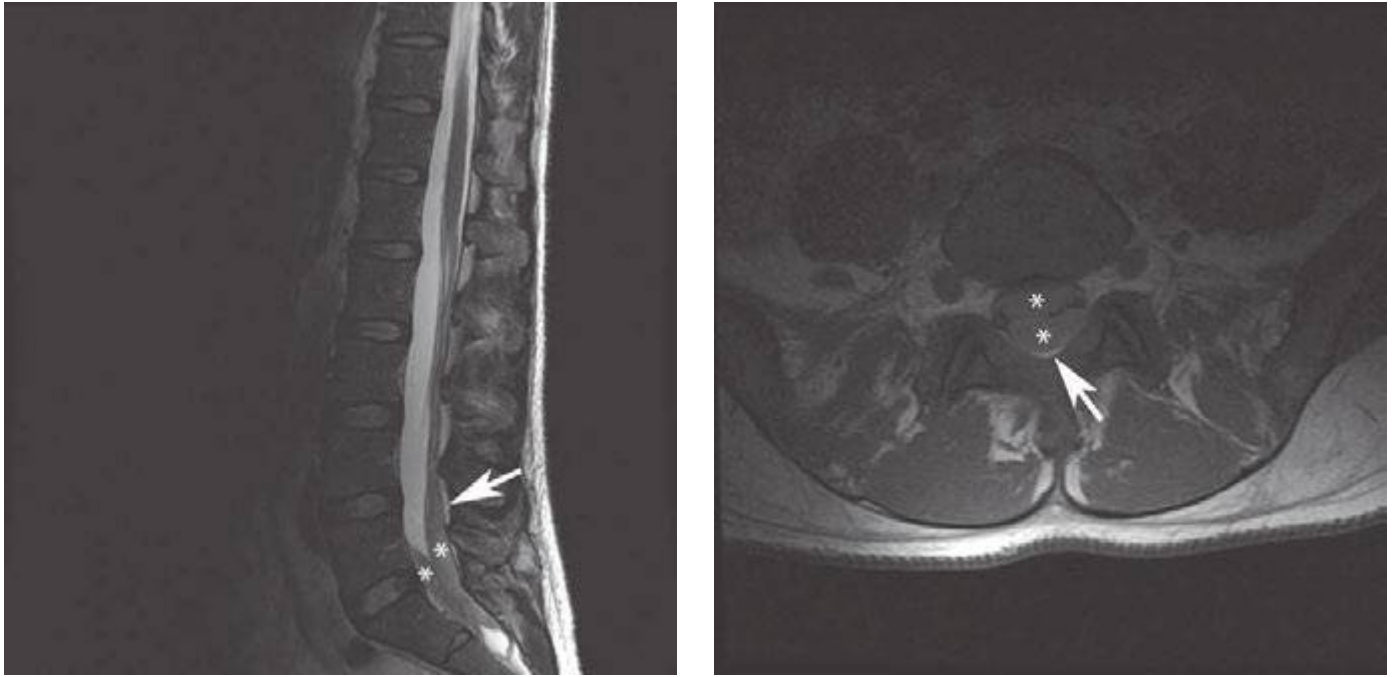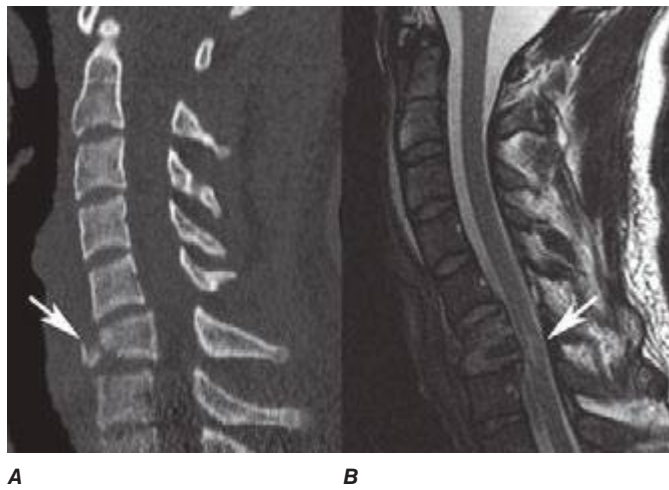


**FIGURE 441e-40 Subdural hematoma.** Sagittal T2-weighted MRI (**A**) and axial noncontrast T1-weighted MRI (**B**) demonstrate subdural collection in the lumbosacral region (\*\*). Note that the epidural fat is compressed but not involved (*arrow*).



**FIGURE 441e-41 Teardrop fracture.** Sagittal CT (**A**) demonstrates fracture line separating the anteroinferior corner of C6 (*arrow*). Sagittal T2-weighted MRI (**B**) displays cord injury (*arrow*).