

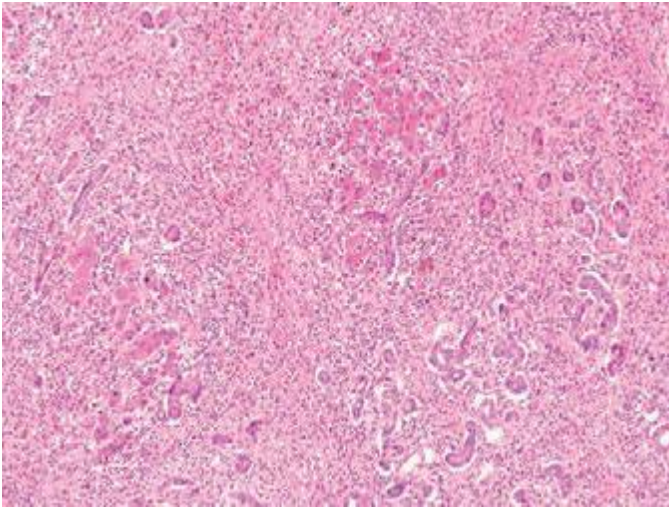FIGURE 366e-28 Acute hepatitis with submassive hepatic necrosis with marked parenchymal collapse, remnant islands of surviving hepatocytes, and a marked ductular reaction (H&E, 10 \times).

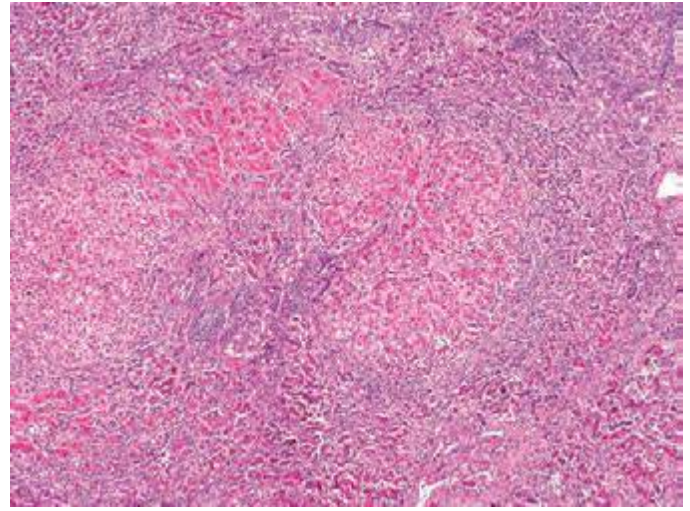


FIGURE 366e-29 Wilson's disease showing cirrhosis, extensive collapse, and ductular reaction in a teenager with an acute presentation (H&E, 4 \times).

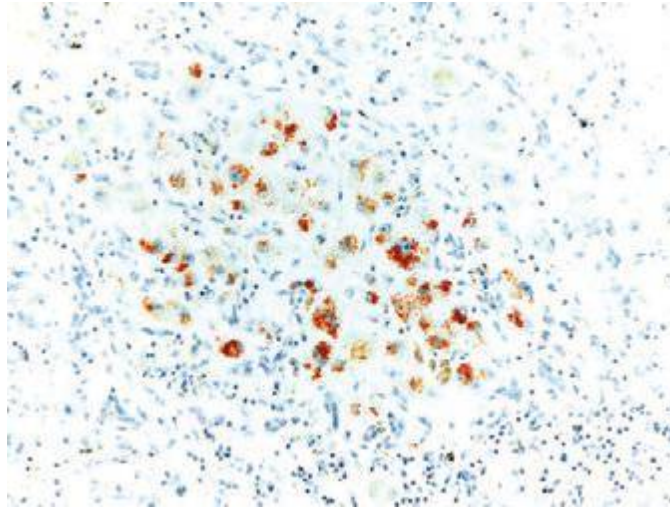


FIGURE 366e-30 Wilson's disease showing extensive hepatocyte cytoplasmic red granular staining for copper in a cirrhotic nodule (rhodanine copper stain, 20 \times).