

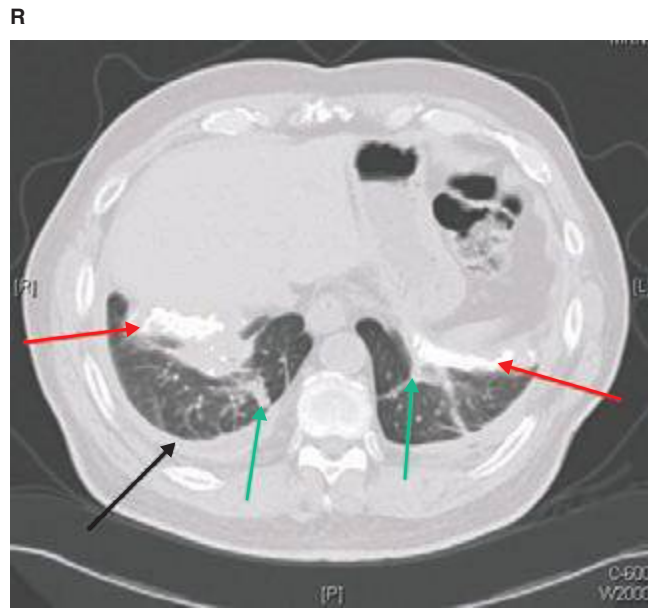FIGURE 308e-43 Asbestosis. Note calcified pleural plaques (*red arrows*), pleural thickening (*black arrow*), and subpleural atelectasis (*green arrows*).

NODULES AND MASSES

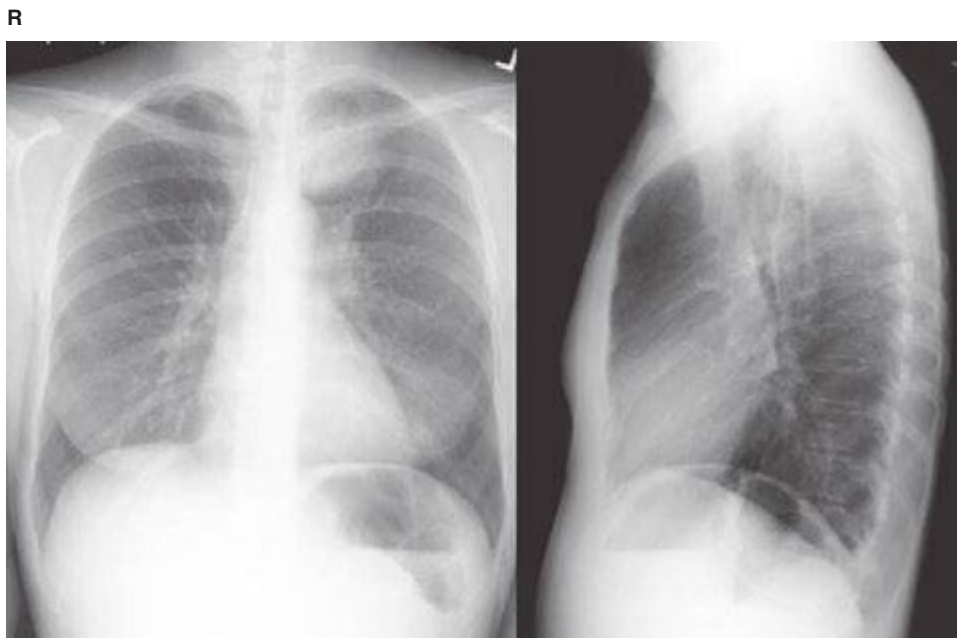


FIGURE 308e-44 Left upper lobe mass, which biopsy revealed to be squamous cell carcinoma.