

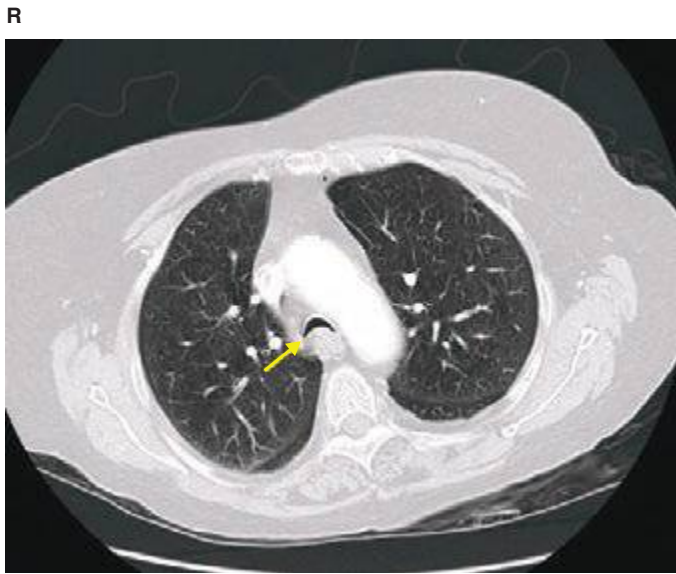FIGURE 308e-37 CT scan demonstrating tracheomalacia (*yellow arrow*). Tracheomalacia is dynamic collapse of the trachea, most prominent during exhalation, due to loss of cartilaginous support.

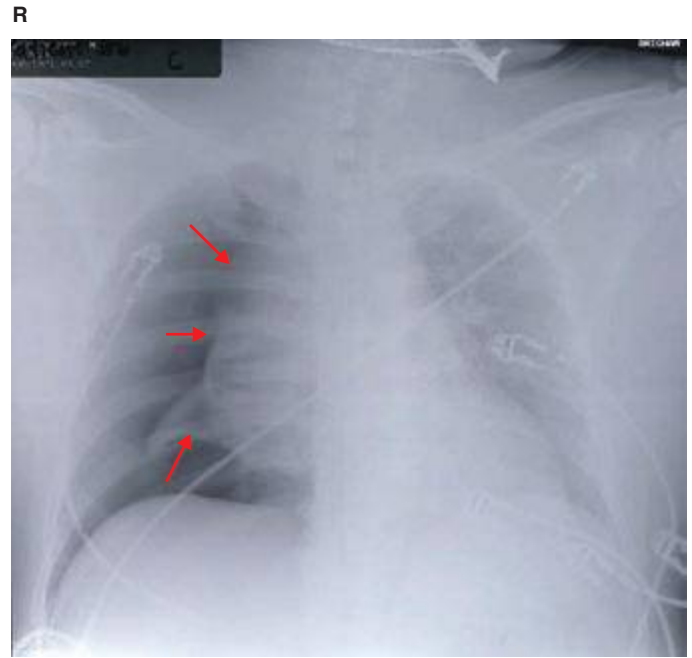


FIGURE 308e-38 Large right pneumothorax with near complete collapse of right lung. Pleural reflection highlighted with *red arrows*.

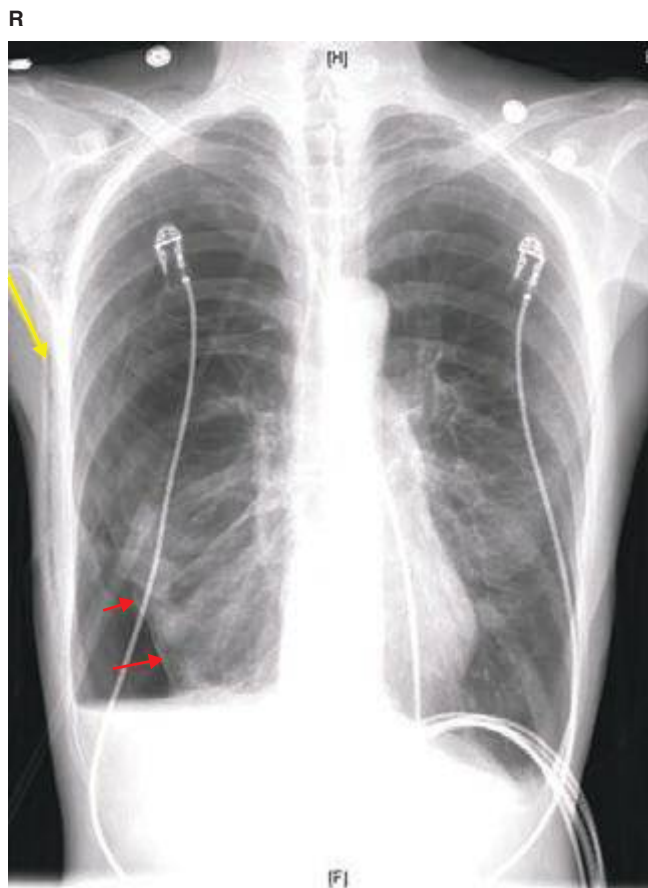


FIGURE 308e-39 Basilar pneumothorax with visible pleural reflection (*red arrows*). Also note, patient has subcutaneous emphysema (*yellow arrow*).