

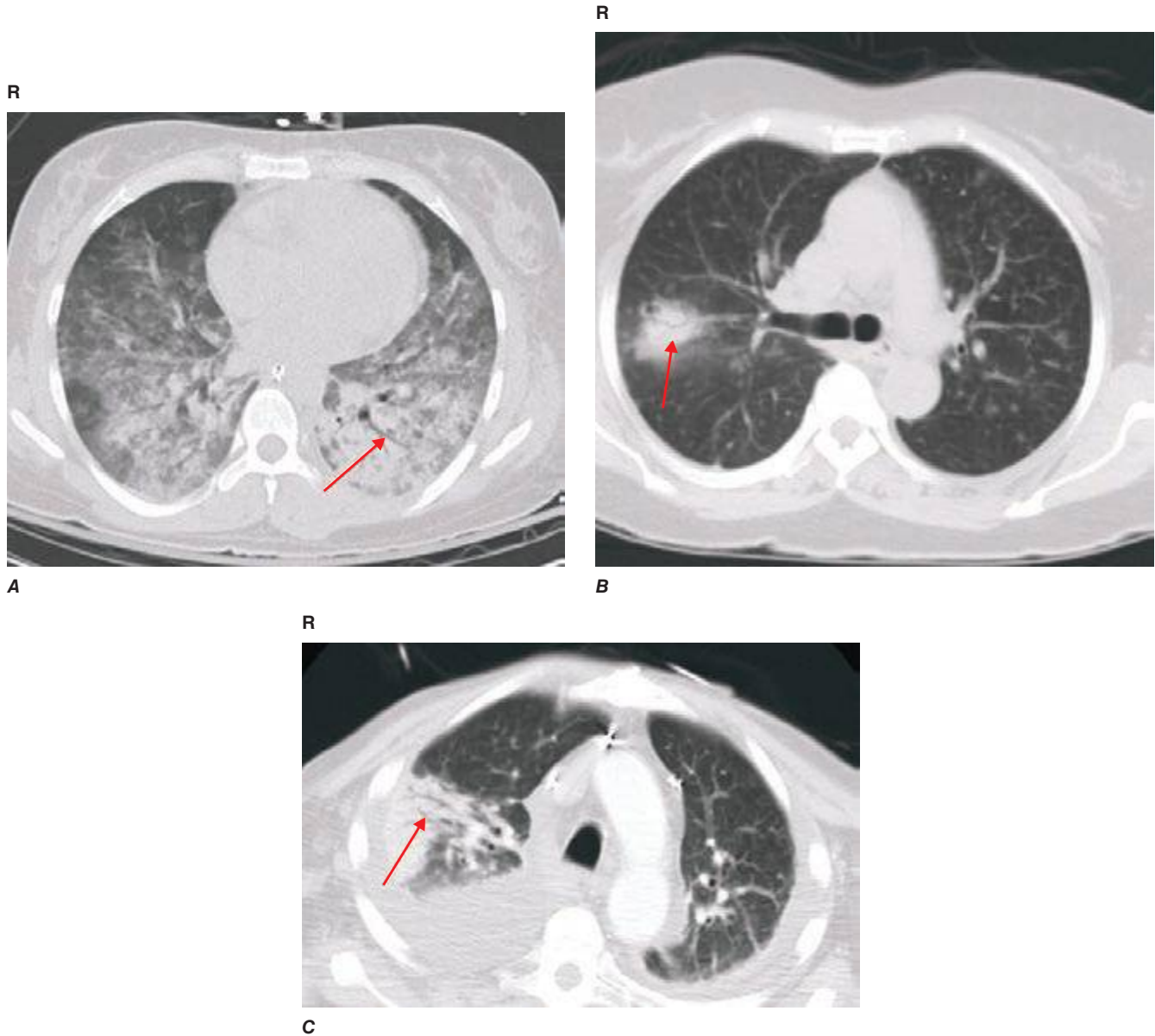FIGURE 308e-32 Three examples of air bronchograms (red arrows) on chest CT.

BRONCHIECTASIS AND AIRWAY ABNORMALITIES

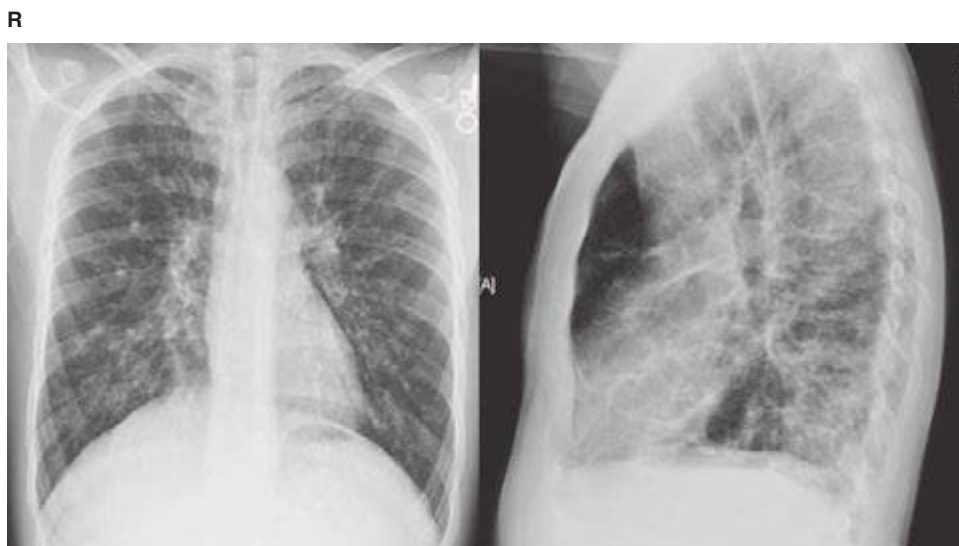


FIGURE 308e-33 Cystic fibrosis with bronchiectasis, apical disease.