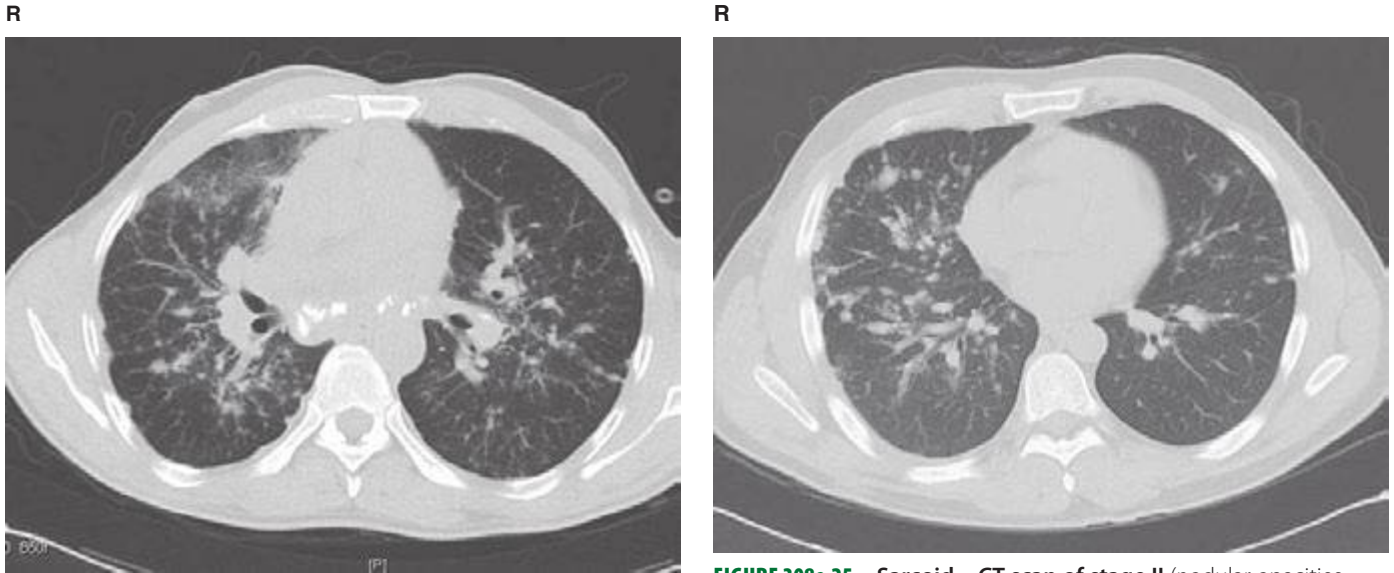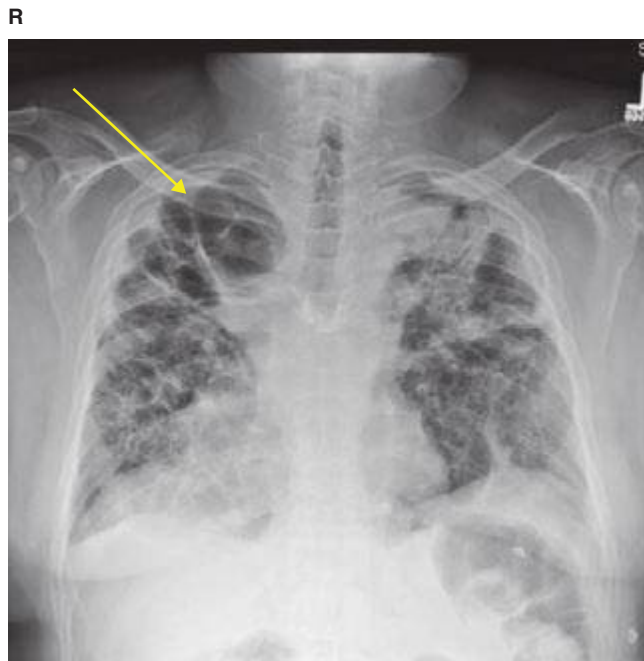


**FIGURE 308e-24** Sarcoid—CT scan of stage II (calcified lymphadenopathy, parenchymal infiltrates).

**FIGURE 308e-25** Sarcoid—CT scan of stage II (nodular opacities tracking along bronchovascular bundles).



**FIGURE 308e-26** Sarcoid—stage IV with fibrotic lung disease and cavitary areas (yellow arrow).