

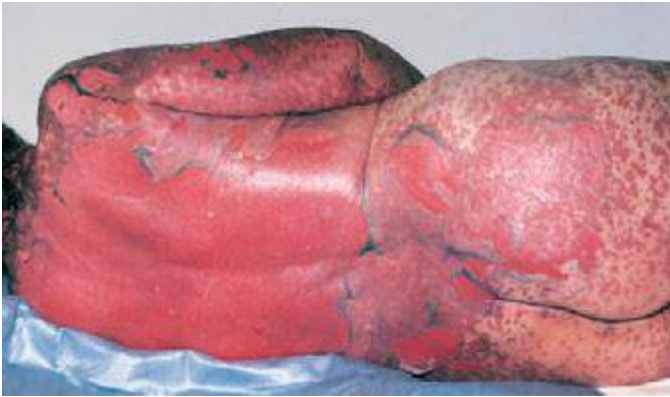

FIGURE 25e-27 Erythema progressing to bullae with resulting sloughing of the entire thickness of the epidermis occurs in toxic epidermal necrolysis. This reaction was due to a sulfonamide. (Reprinted from K Wolff, RA Johnson: *Color Atlas and Synopsis of Clinical Dermatology*, 5th ed. New York, McGraw-Hill, 2005.)

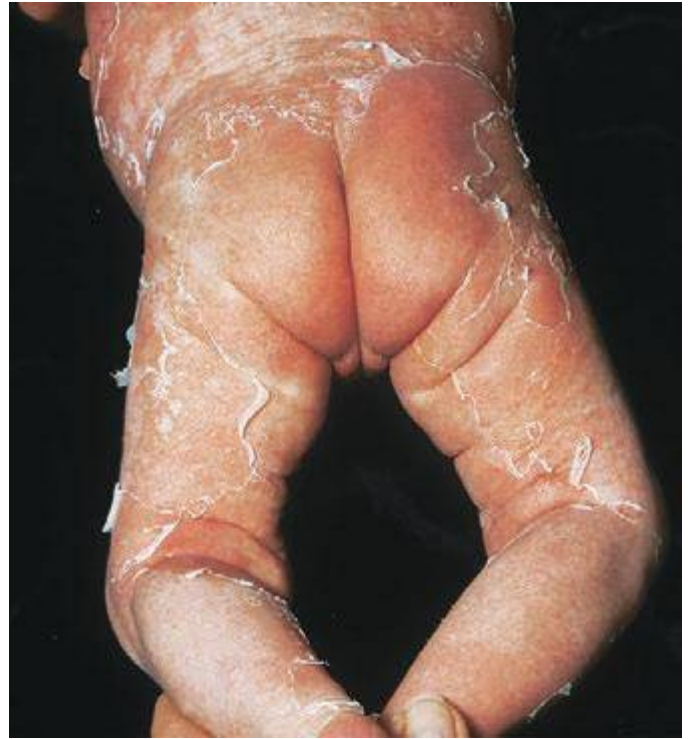

FIGURE 25e-29 This infant with staphylococcal scalded skin syndrome demonstrates generalized desquamation. (Reprinted from K Wolff, RA Johnson: *Color Atlas and Synopsis of Clinical Dermatology*, 6th ed. New York, McGraw-Hill, 2009.)

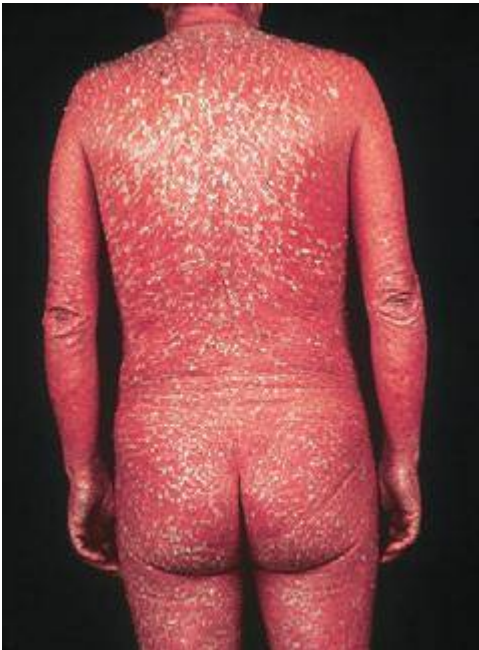


FIGURE 25e-28 Diffuse erythema and scaling are present in this patient with psoriasis and the exfoliative erythroderma syndrome. (Reprinted from K Wolff, RA Johnson: *Color Atlas and Synopsis of Clinical Dermatology*, 6th ed. New York, McGraw-Hill, 2009.)

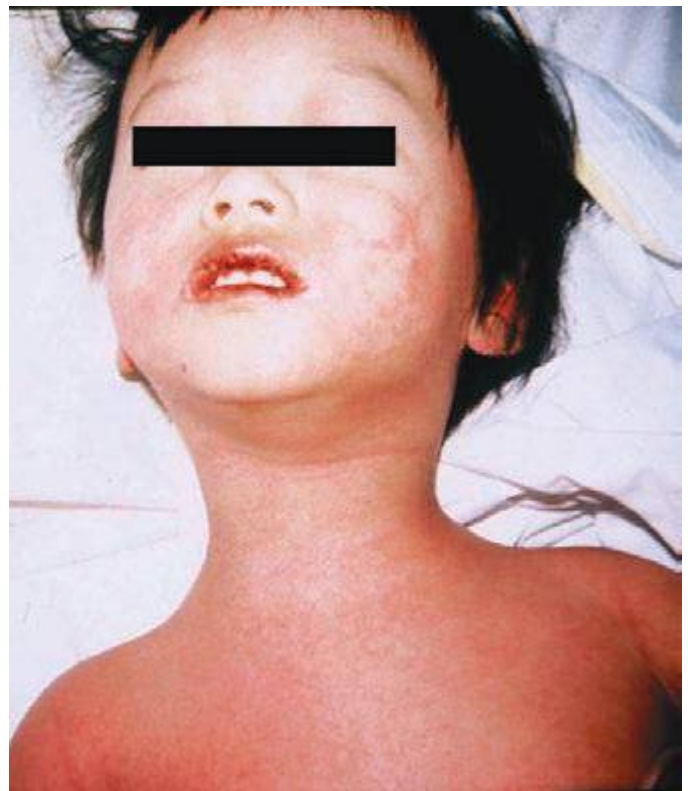

FIGURE 25e-30 Fissuring of the lips and an erythematous exanthem are evident in this patient with Kawasaki disease. (Courtesy of Stephen E. Gellis, MD; with permission.)