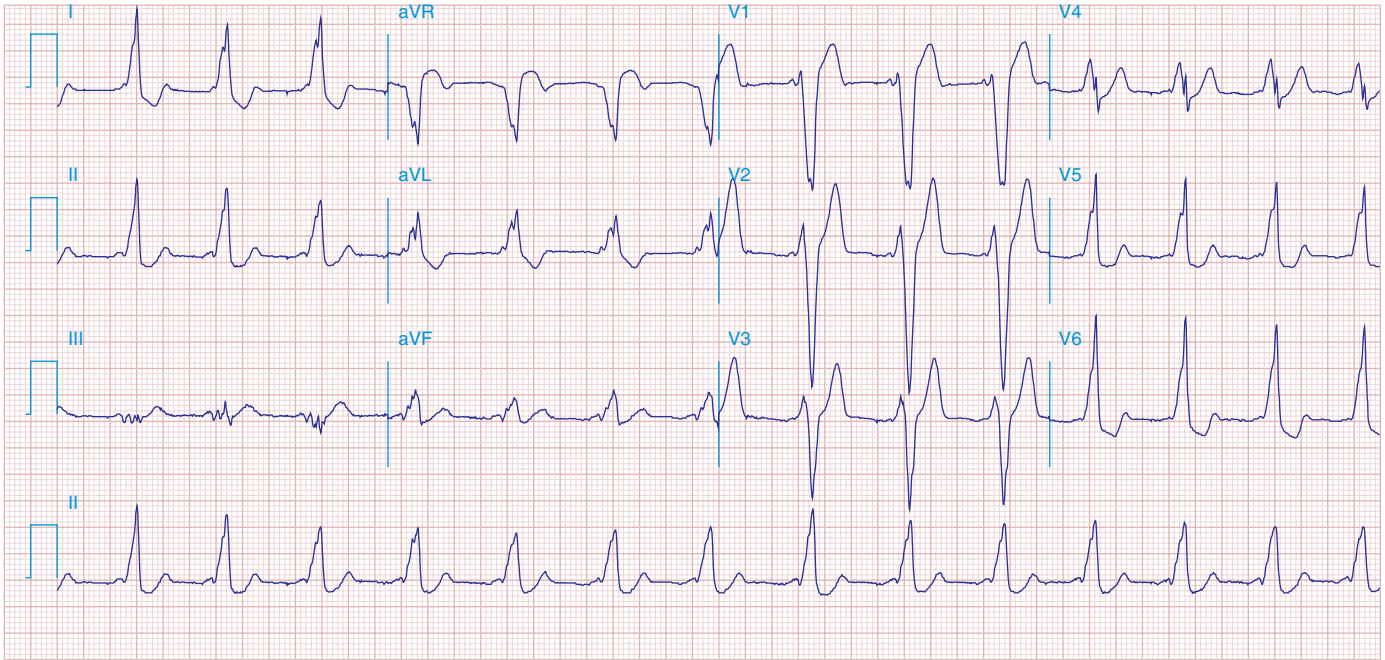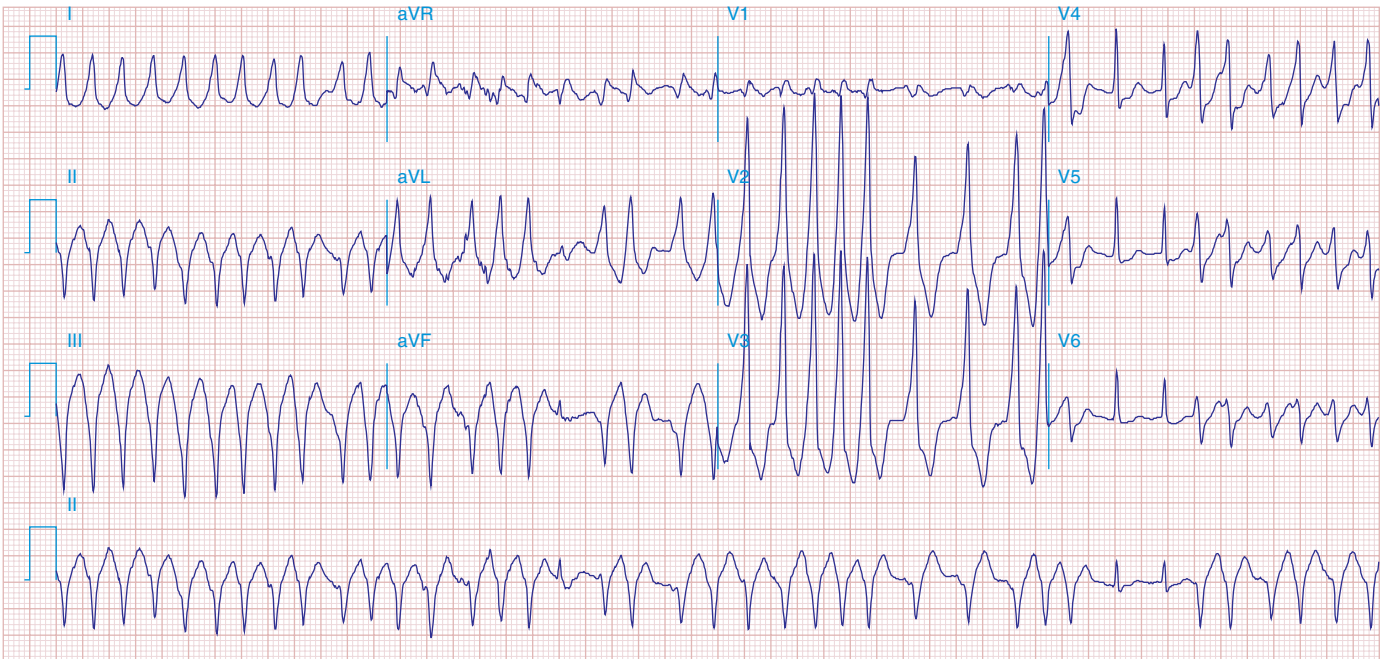


**FIGURE 278e-20** WPW preexcitation pattern, with triad of short PR, wide QRS, and delta waves. Polarity of the delta waves (slightly positive in leads  $V_1$  and  $V_2$  and most positive in lead II and lateral chest leads) is consistent with a right-sided bypass tract.



**FIGURE 278e-21** AF in patient with the WPW syndrome and antegrade conduction down the bypass tract leading to a wide complex tachycardia. Rhythm is "irregularly irregular," and rate is extremely rapid (about 230/min). Not all beats are preexcited.