

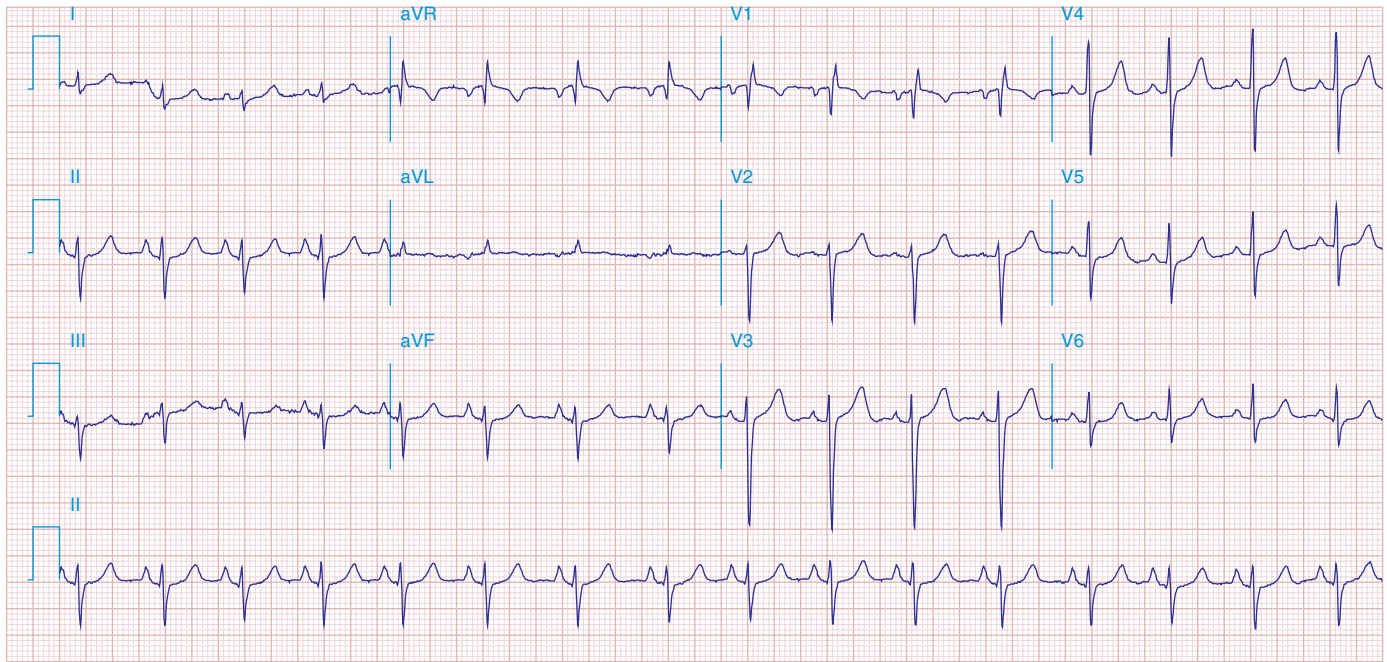FIGURE 269e-22 Signs of right atrial/RV overload in a patient with chronic obstructive lung disease: (1) peaked P waves in II; (2) QR in V_1 with narrow QRS; (3) delayed precordial transition, with terminal S waves in V_5/V_6 ; (4) superior axis deviation with an S_1 - S_2 - S_3 pattern.

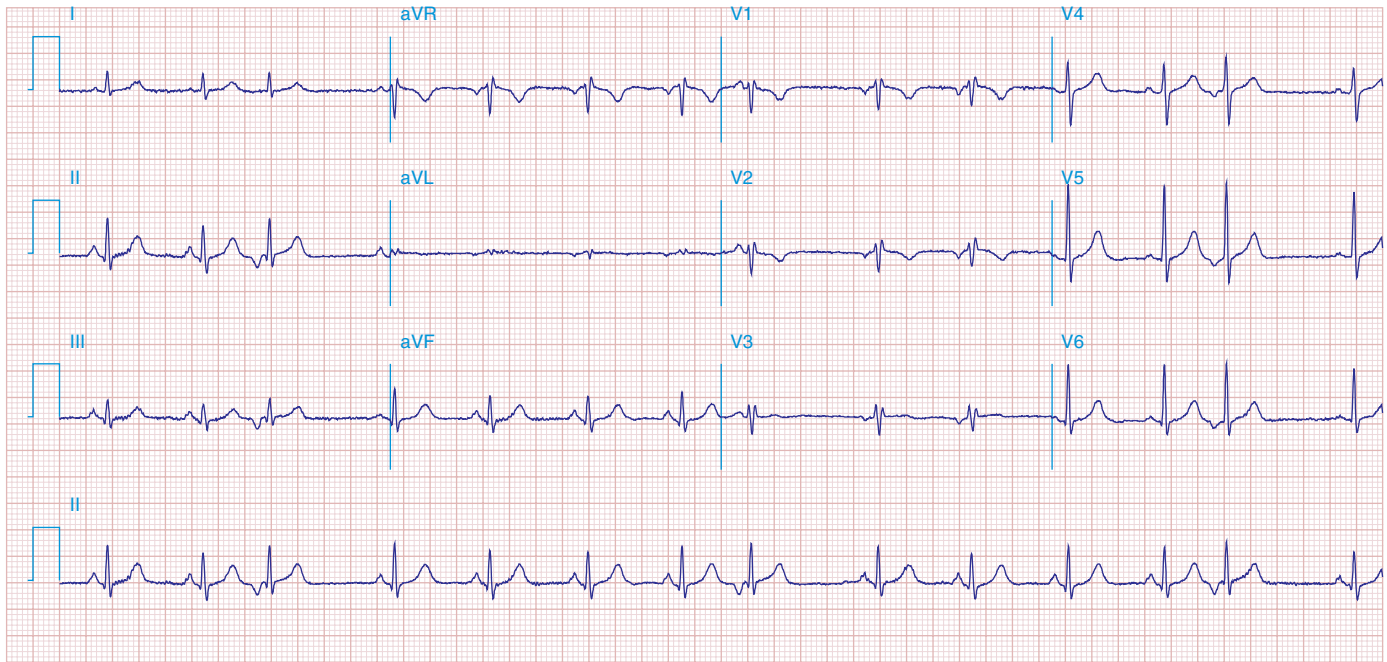


FIGURE 269e-23 (1) Low voltage; (2) incomplete RBBB (rsr' in V_1 - V_3); (3) borderline peaked P waves in lead II with vertical P-wave axis (probable right atrial overload); (4) slow R-wave progression in V_1 - V_3 ; (5) prominent S waves in V_6 ; and (6) atrial premature beats. This combination is seen typically in severe chronic obstructive lung disease.