

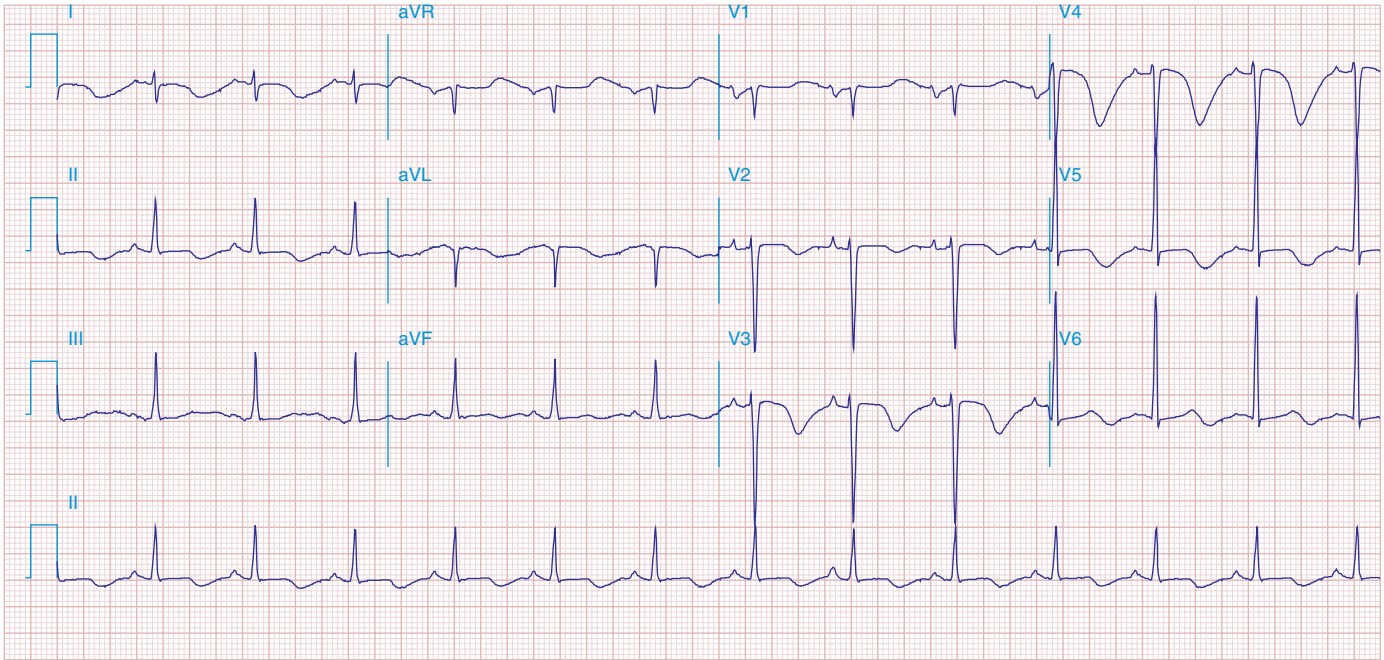FIGURE 269e-16 SR, left atrial abnormality, and LVH by voltage criteria with borderline right-axis deviation in a patient with mixed mitral stenosis (left atrial abnormality and right-axis deviation) and mitral regurgitation (LVH). Prominent precordial T-wave inversions and QT prolongation also present.

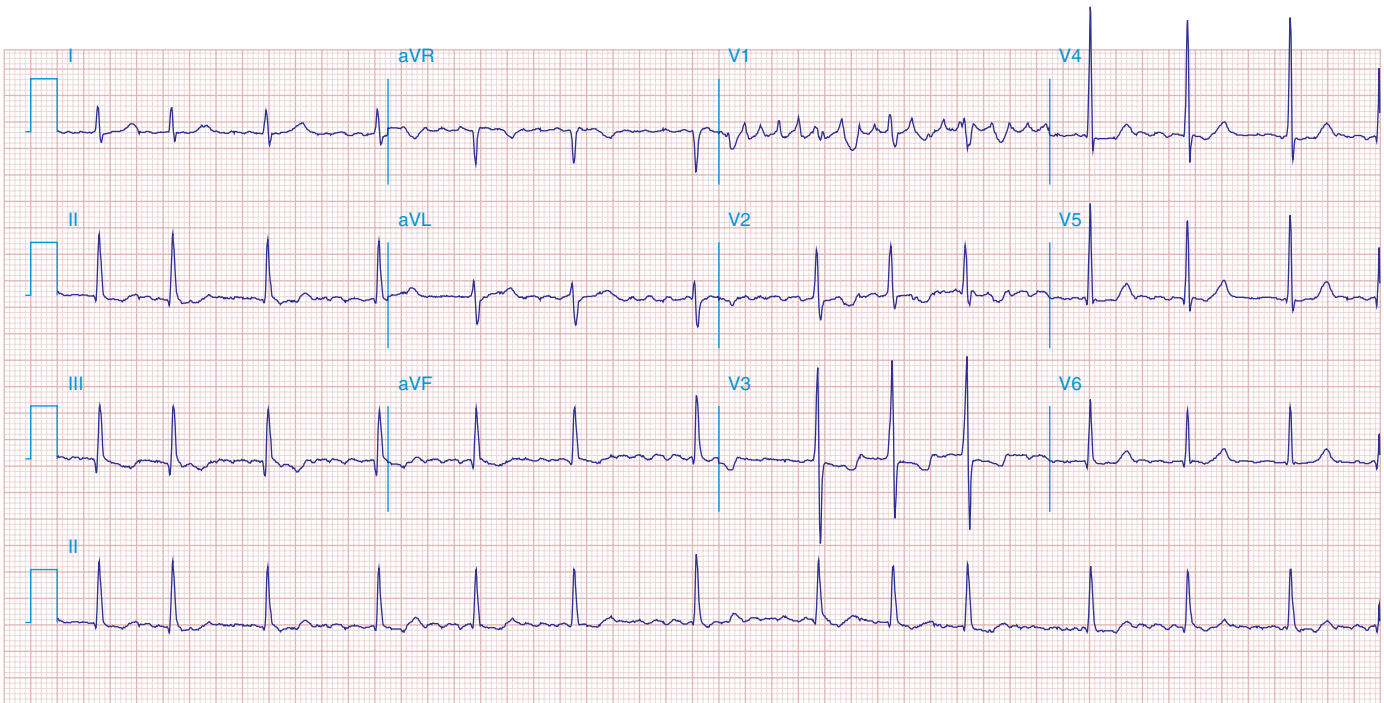


FIGURE 269e-17 Coarse AF, tall R in V_2 with vertical QRS axis (positive R in aVF) indicating RVH. Tall R in V_4 may be due to concomitant LVH. Patient had severe mitral stenosis with moderate mitral regurgitation.