

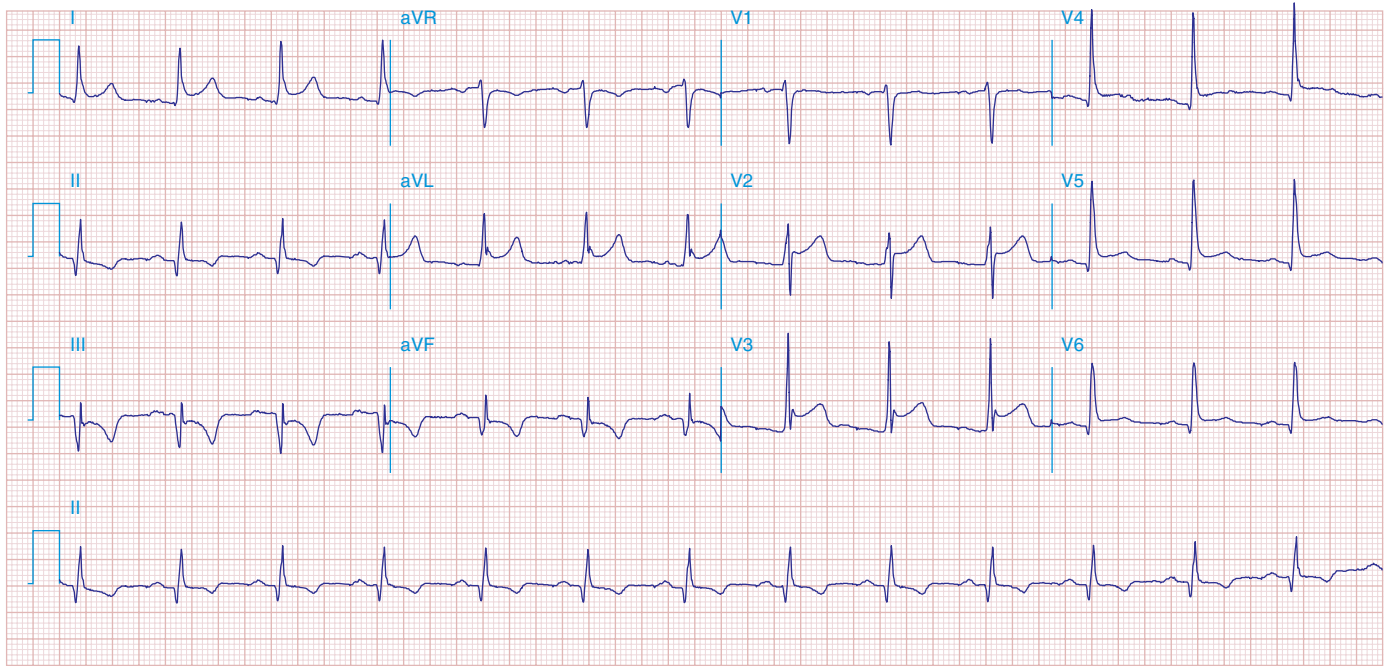FIGURE 269e-14 SR; diffuse ST elevations (I, II, aVL, aVF, V₂-V₆) with associated PR deviations (elevated PR in aVR; depressed in V₄-V₆); borderline low voltage. Q-wave and T-wave inversions in II, III, and aVF. Diagnosis: acute pericarditis with inferior Q-wave MI.

VALVULAR HEART DISEASE AND HYPERTROPHIC CARDIOMYOPATHY

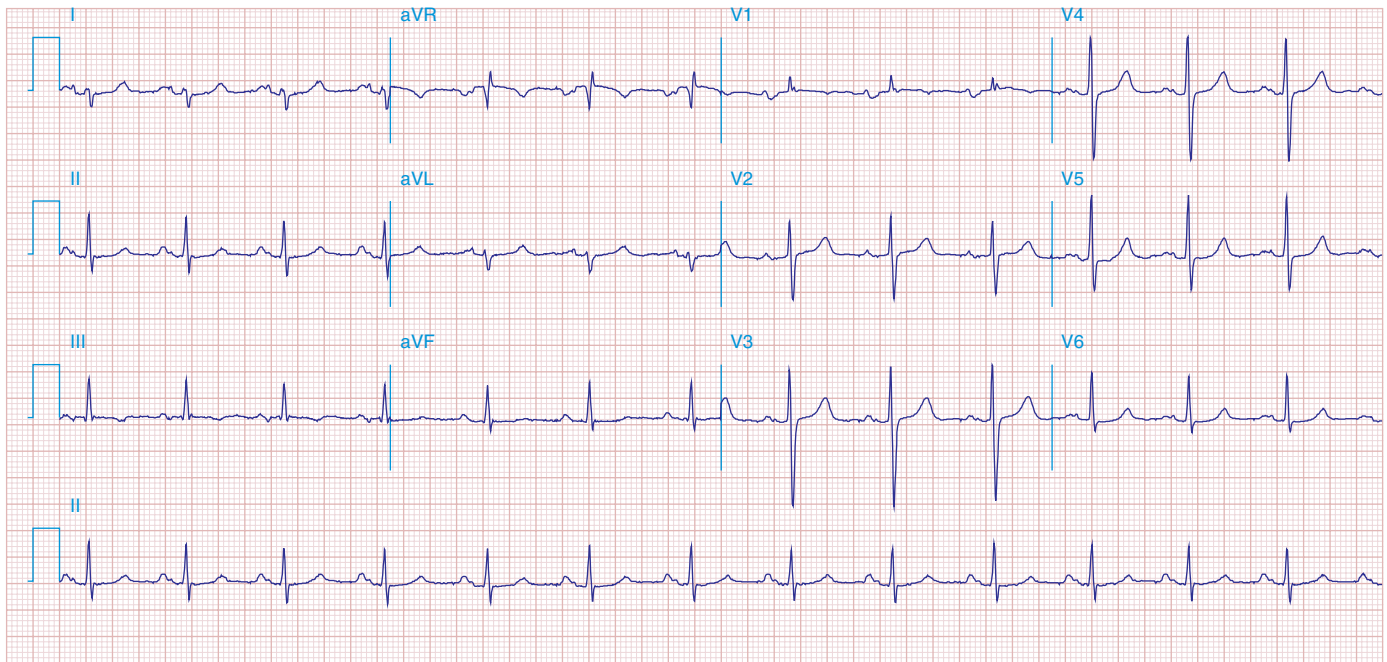


FIGURE 269e-15 SR, prominent left atrial abnormality (see I, II, V₁), right-axis deviation, and RVH (tall, relatively narrow R wave in V₁) in a patient with mitral stenosis.