

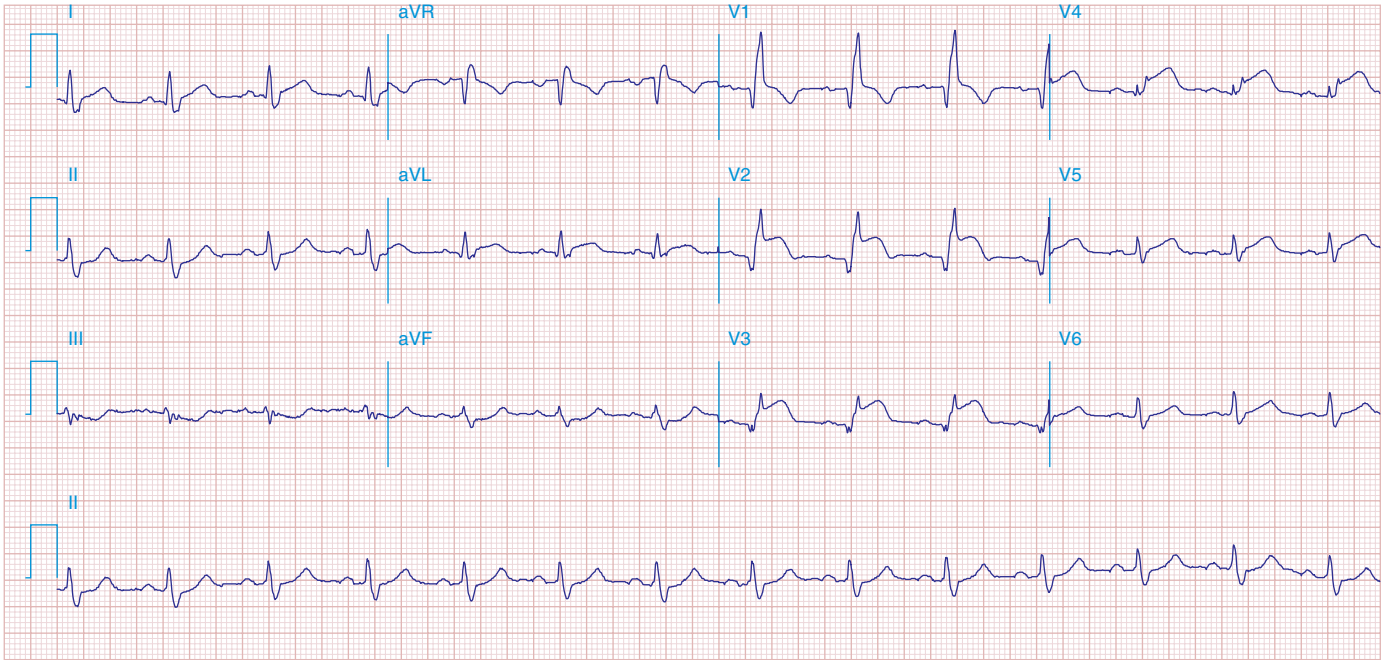FIGURE 269e-8 Acute anteroseptal MI (Q waves and ST elevations in V_1 – V_4) with RBBB (note terminal R waves in V_1).

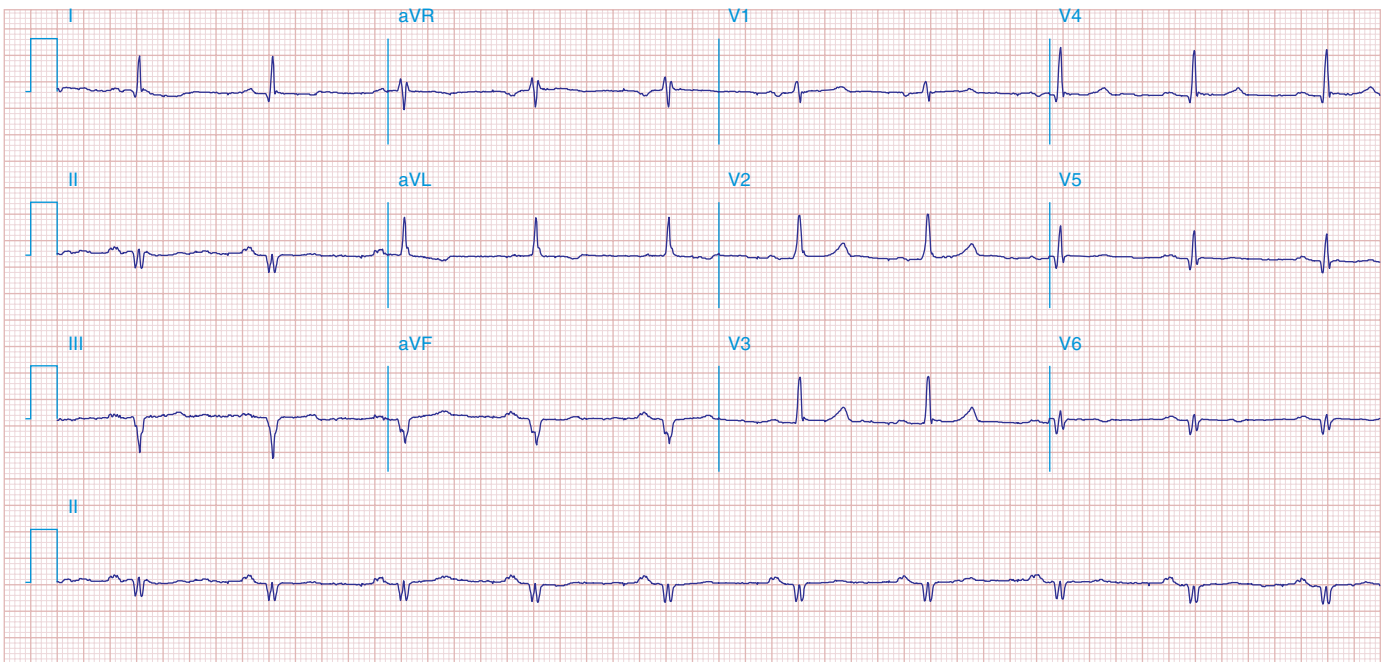


FIGURE 269e-9 Extensive prior MI involving inferior-posterior-lateral wall (Q waves in leads II, III, aVF, tall R waves in V_1 , V_2 , and Q waves in V_5 , V_6). T-wave abnormalities in leads I and aVL, V_5 , and V_6 .