

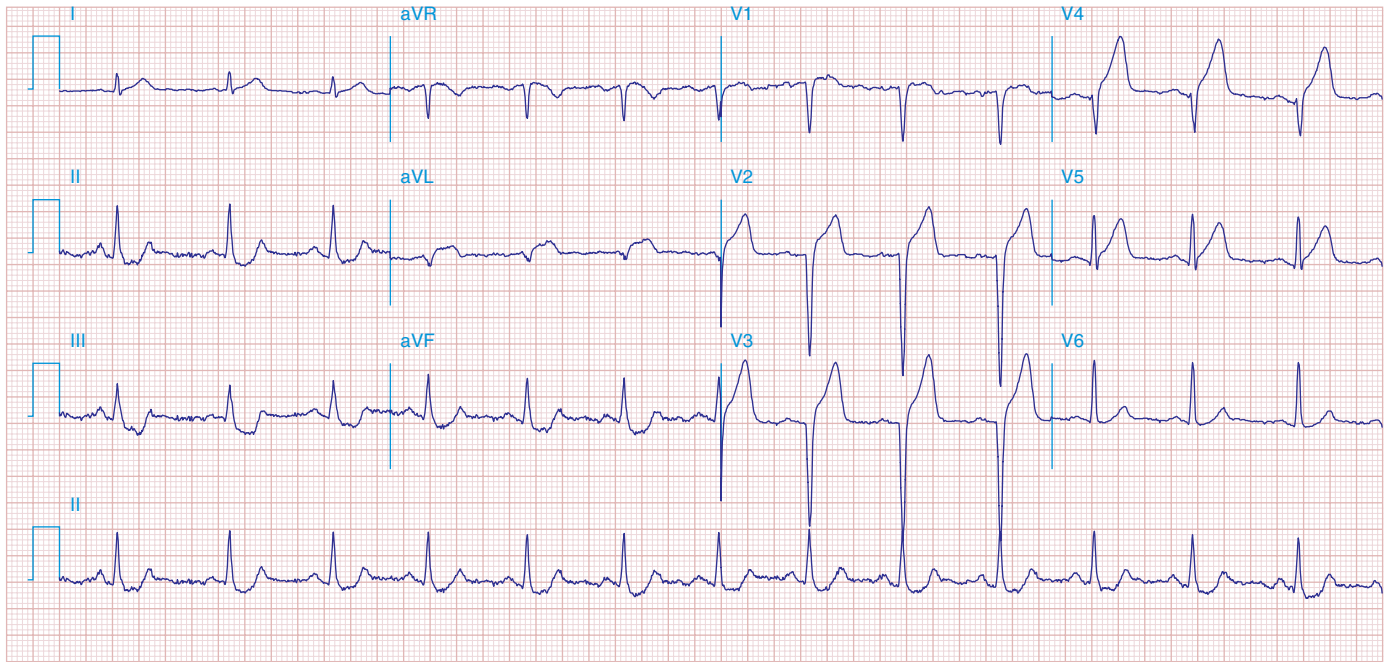FIGURE 269e-6 Acute anterior wall MI with ST elevations and Q waves in V_1 - V_4 and aVL and reciprocal inferior ST depressions.

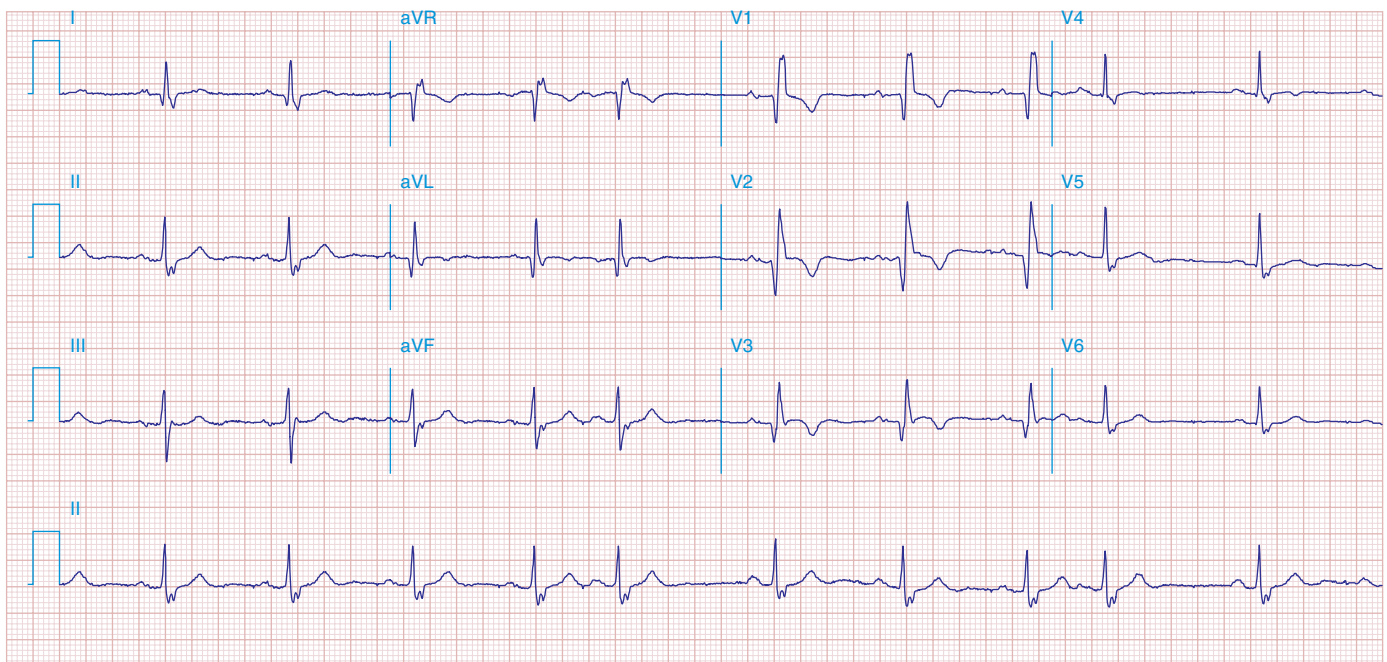


FIGURE 269e-7 SR with premature atrial complexes. RBBB; pathologic Q waves and ST elevation due to acute anterior/septal MI in V_1 - V_3 .