

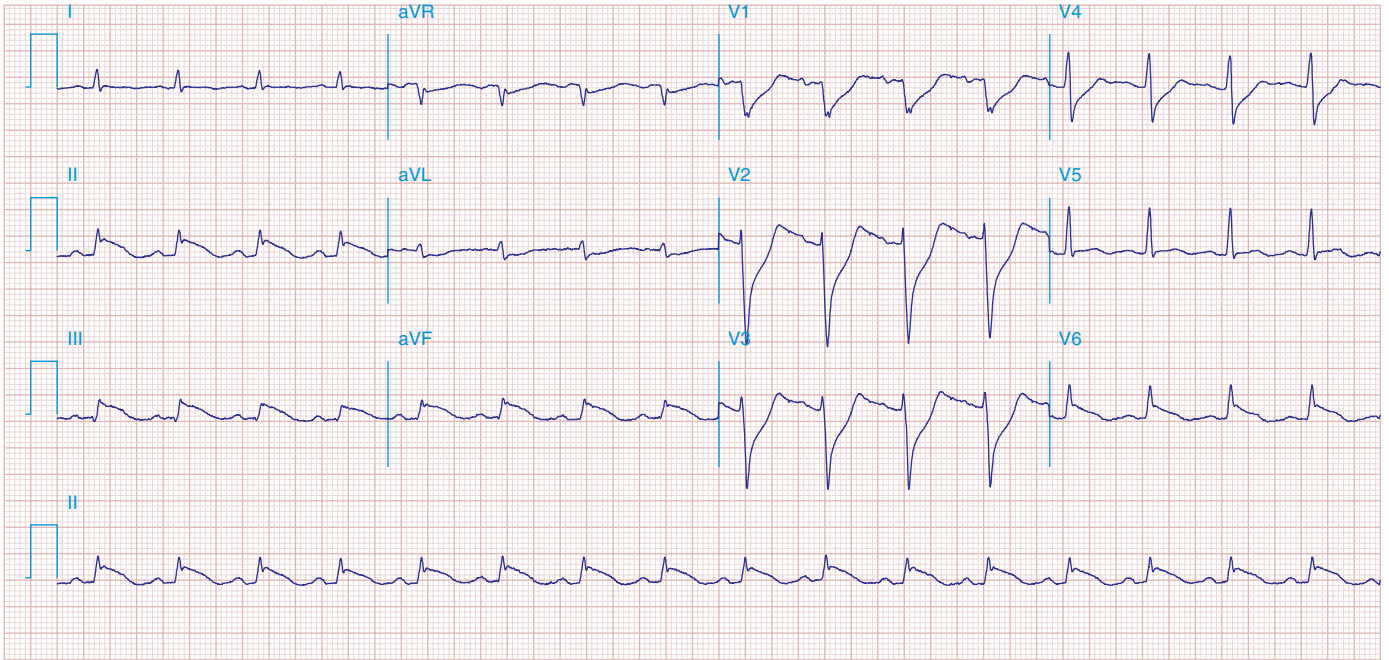FIGURE 269e-4 Sinus tachycardia. Marked ischemic ST-segment elevations in inferior limb leads (II, III, aVF) and laterally (V_6) suggestive of acute inferolateral MI, and prominent ST-segment depressions with upright T waves in V_1 - V_4 are consistent with associated acute posterior MI.

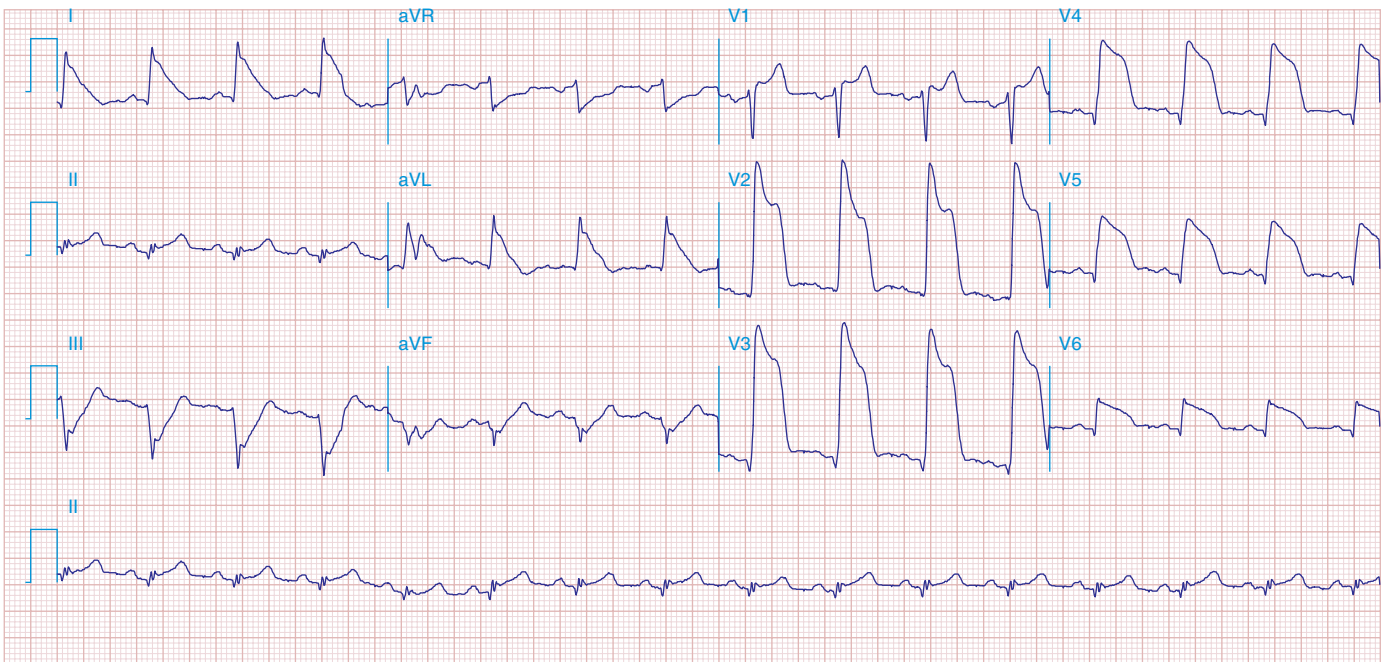


FIGURE 269e-5 Acute, extensive anterior MI with marked ST elevations in I, aVL, V_1 - V_6 and low amplitude pathologic Q waves in V_3 - V_6 . Marked reciprocal ST-segment depressions in III and aVF.