

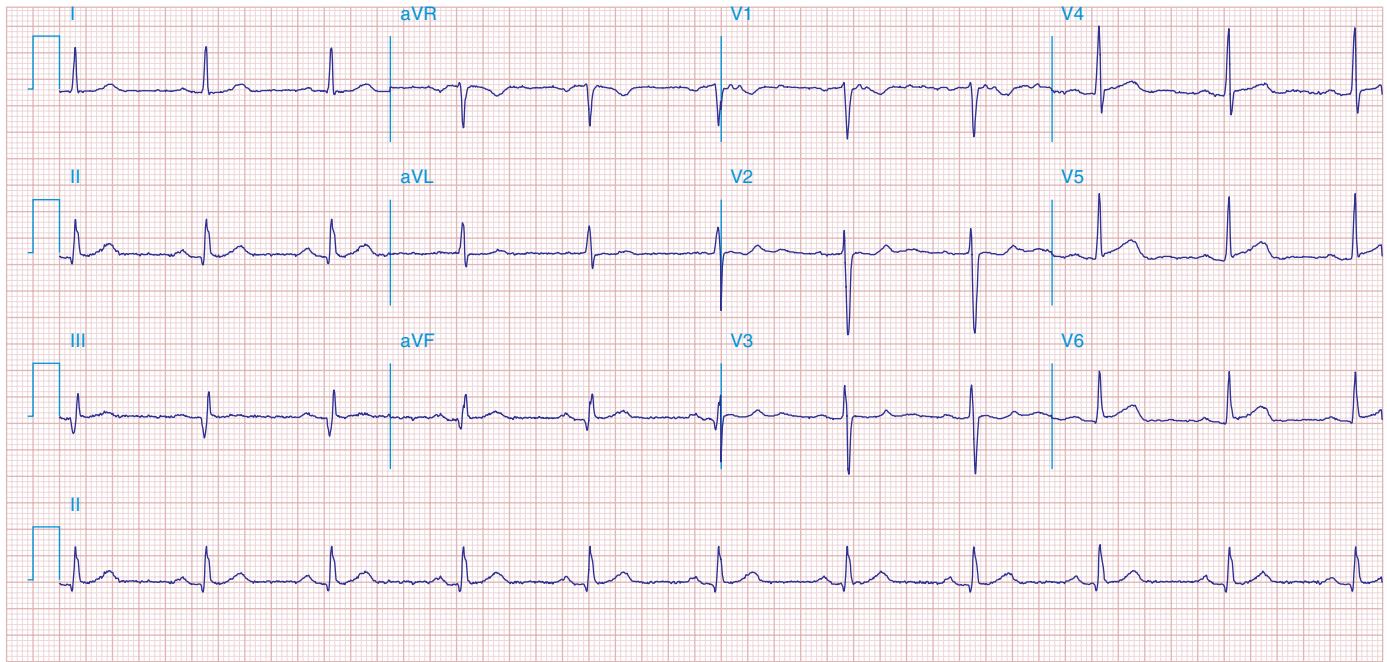FIGURE 269e-2 Acute anterolateral wall ischemia with ST elevations in V_4 – V_6 . Probable prior inferior MI with Q waves in leads II, III, and aVF.

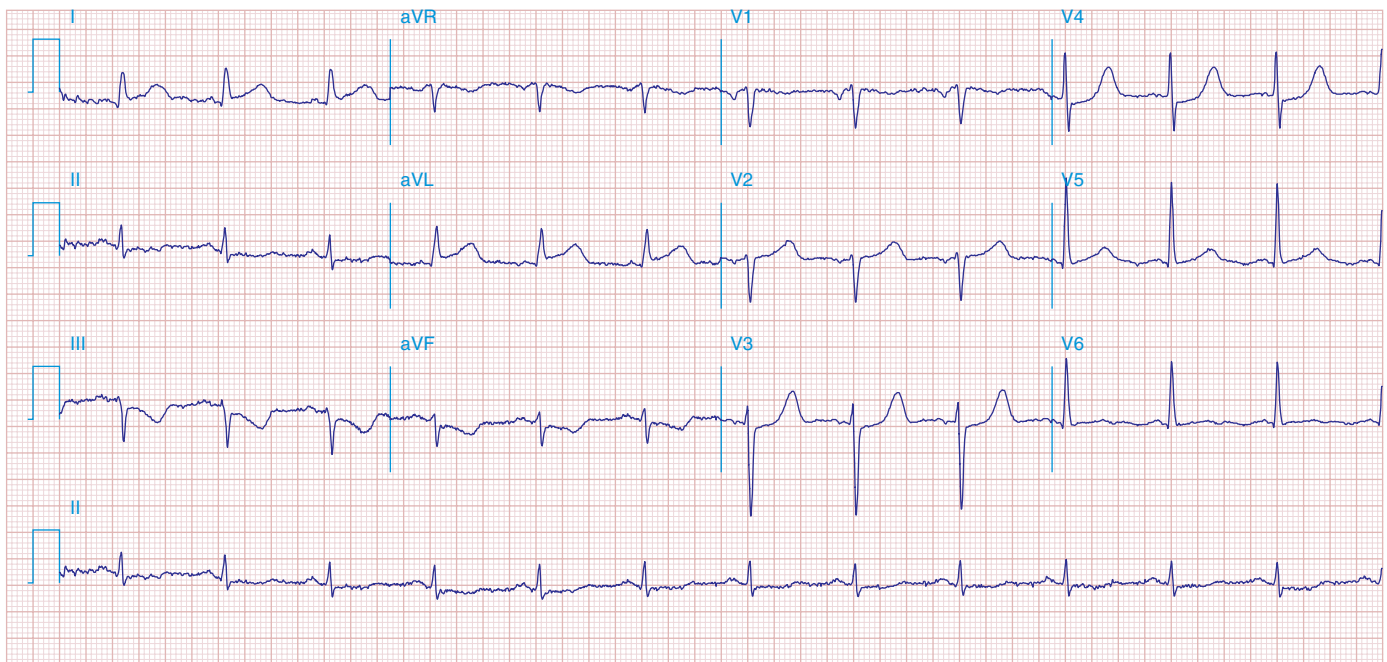


FIGURE 269e-3 Acute lateral ischemia with ST elevations in I and aVL with probable reciprocal ST depressions inferiorly (II, III, and aVF). Ischemic ST depressions also in V_3 and V_4 . Left atrial abnormality.