

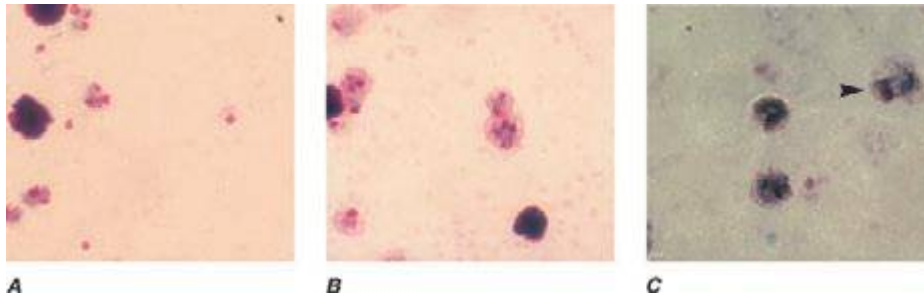FIGURE 250e-7 Thick blood films of *Plasmodium ovale*. **A.** Trophozoites. **B.** Schizonts. **C.** Gametocytes. (Reproduced from *Bench Aids for the Diagnosis of Malaria Infections*, 2nd ed, with the permission of the World Health Organization.)

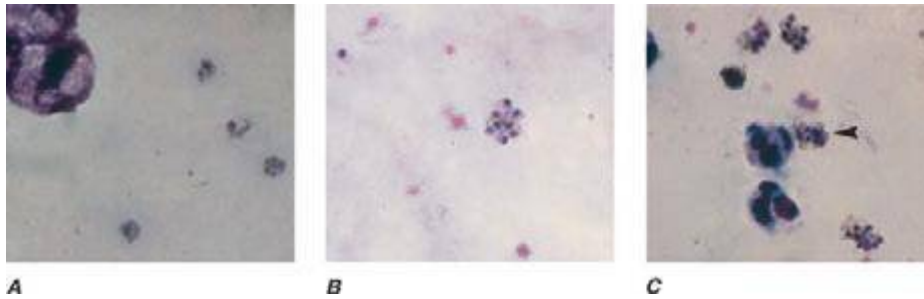


FIGURE 250e-8 Thick blood films of *Plasmodium malariae*. **A.** Trophozoites. **B.** Schizonts. **C.** Gametocytes. (Reproduced from *Bench Aids for the Diagnosis of Malaria Infections*, 2nd ed, with the permission of the World Health Organization.)

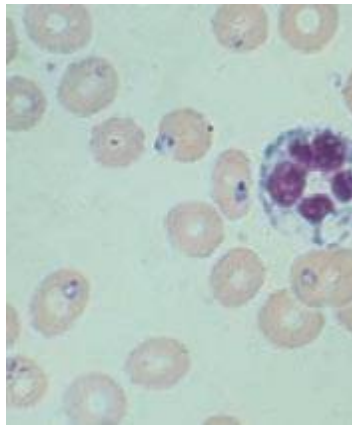


FIGURE 250e-9 Thin blood film showing trophozoites of *Babesia*. (Reproduced from *Bench Aids for the Diagnosis of Malaria Infections*, 2nd ed, with the permission of the World Health Organization.)