

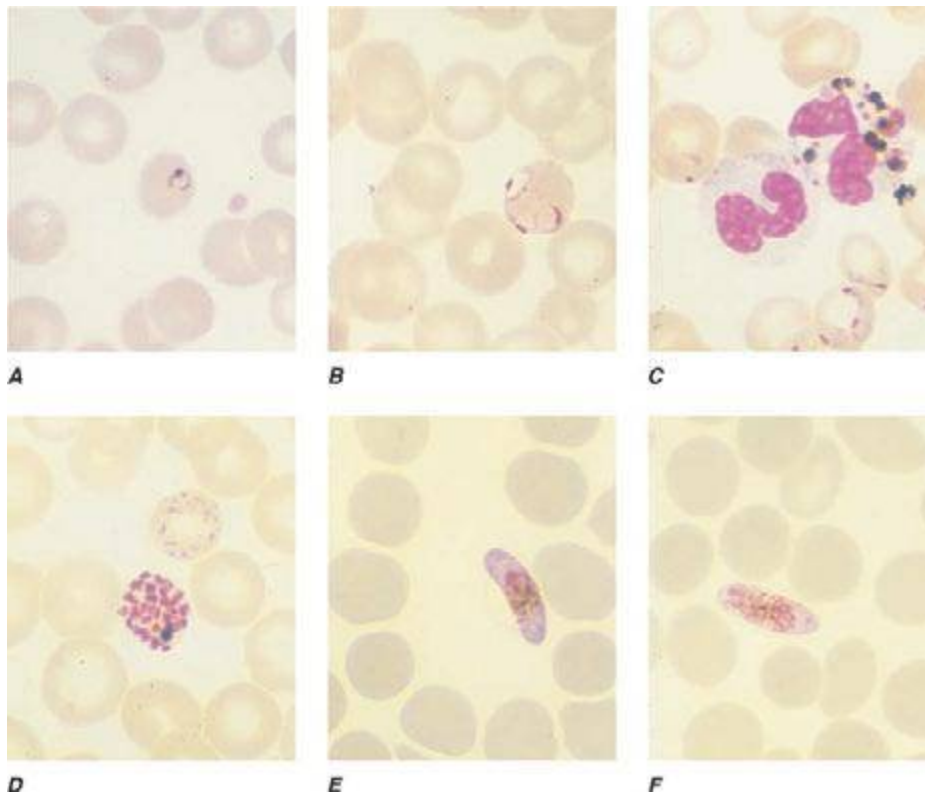FIGURE 250e-1 Thin blood films of *Plasmodium falciparum*. **A.** Young trophozoites. **B.** Old trophozoites. **C.** Pigment in polymorphonuclear cells and trophozoites. **D.** Mature schizonts. **E.** Female gametocytes. **F.** Male gametocytes. (Reproduced from *Bench Aids for the Diagnosis of Malaria Infections*, 2nd ed, with the permission of the World Health Organization.)

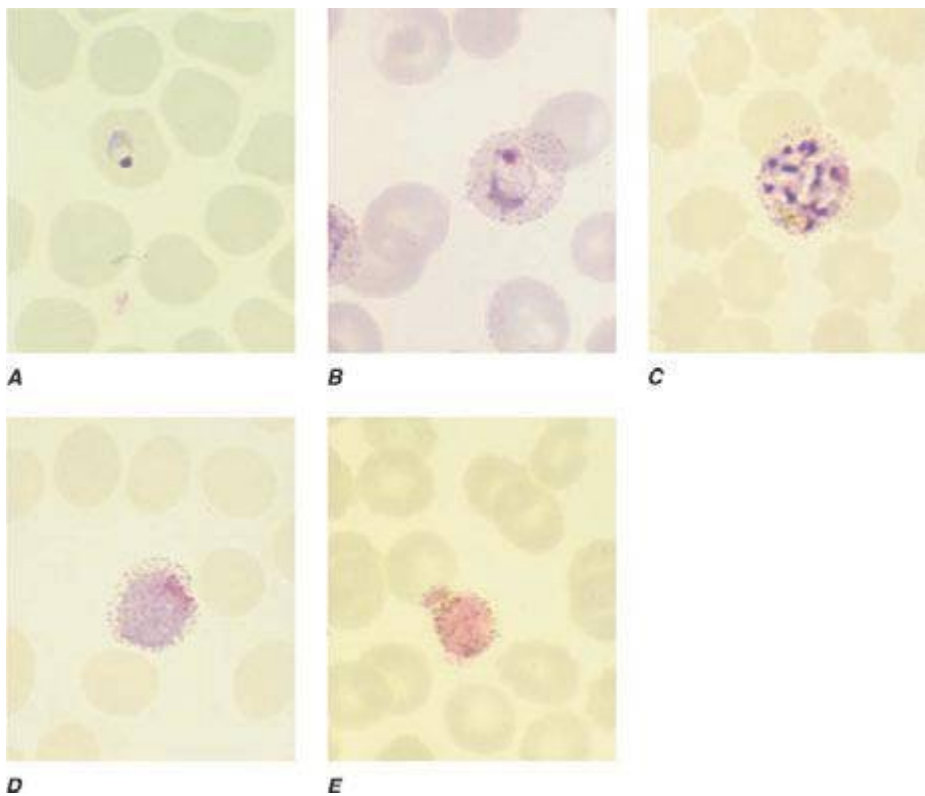


FIGURE 250e-2 Thin blood films of *Plasmodium vivax*. **A.** Young trophozoites. **B.** Old trophozoites. **C.** Mature schizonts. **D.** Female gametocytes. **E.** Male gametocytes. (Reproduced from *Bench Aids for the Diagnosis of Malaria Infections*, 2nd ed, with the permission of the World Health Organization.)