

MOLLUSCUM CONTAGIOSUM

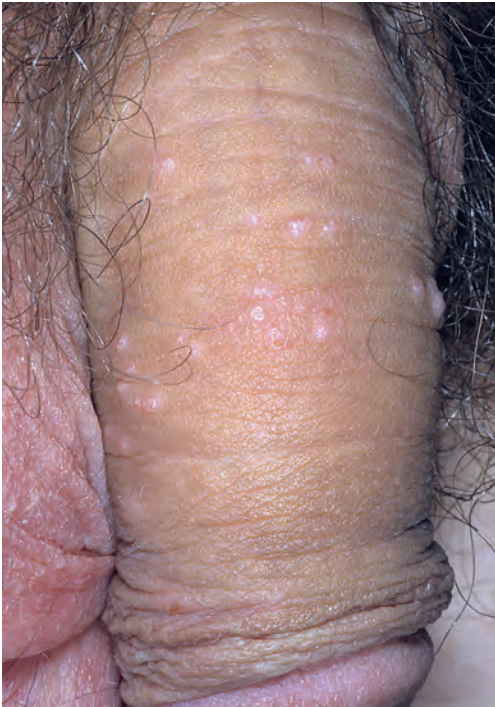

FIGURE 11-21 ■ Molluscum contagiosum must be examined closely to differentiate them from warts, especially in the groin area.

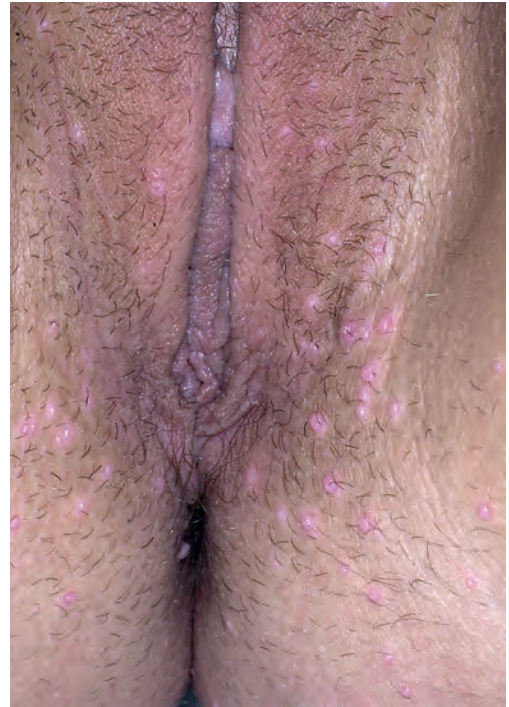


FIGURE 11-22 ■ Molluscum contagiosum is easily misdiagnosed as genital warts. However, compared to warts, the lesions of molluscum contagiosum are never confluent and do not appear as a large mass.

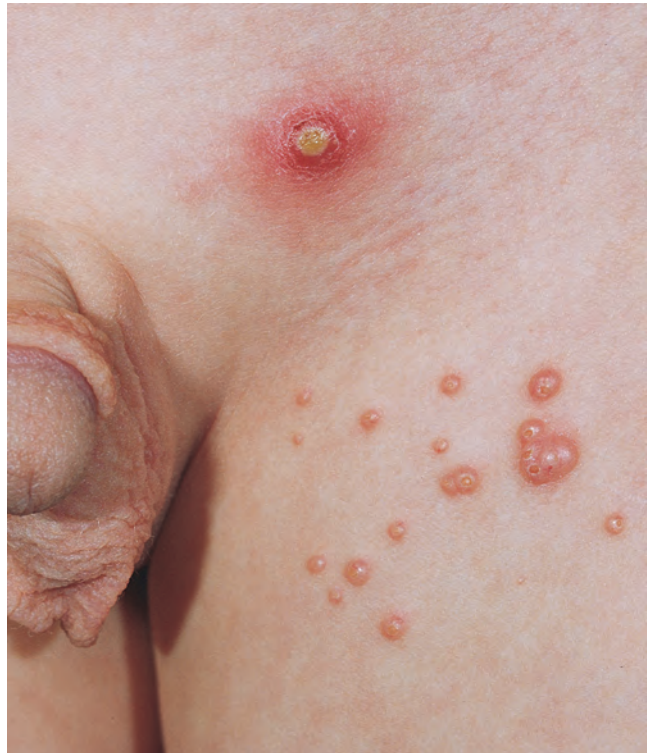
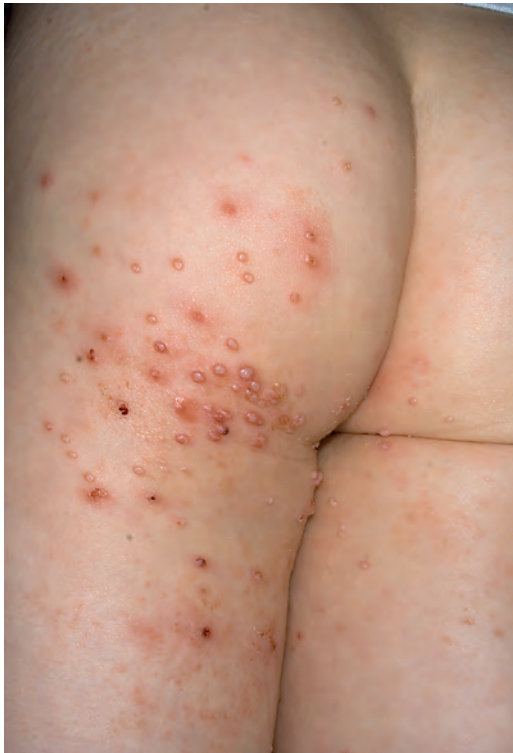
FIGURE 11-23 ■ Molluscum contagiosum. A single lesion (or multiple lesions) may become inflamed and then disappear.