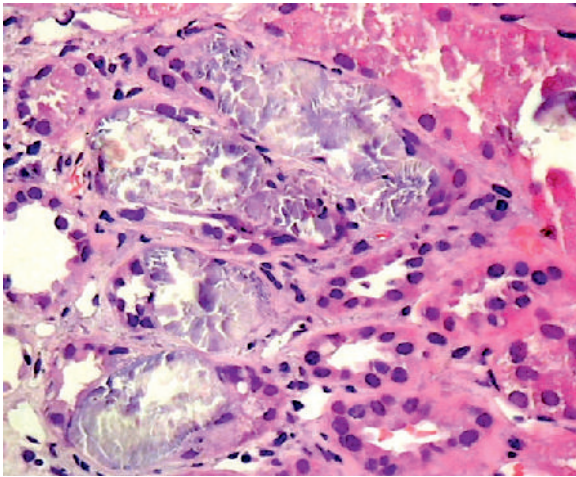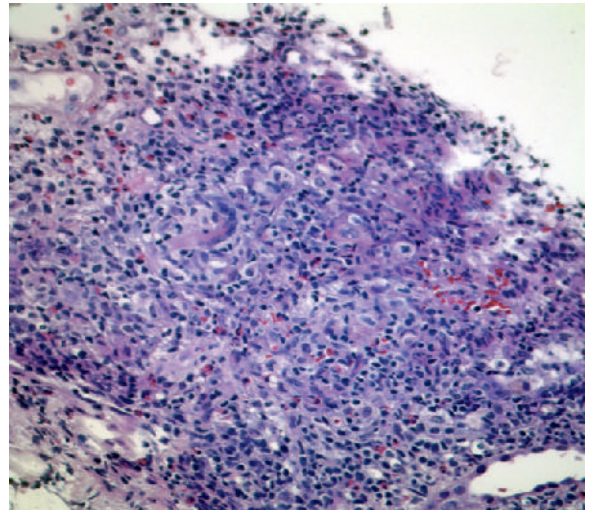


**E-FIGURE 31-5** Oxalate nephropathy. Calcium oxalate crystal deposition in the renal tubules can cause acute kidney injury. The crystals are strongly birefringent crystals on polarized light microscopy.



**E-FIGURE 31-6** Acute kidney injury can result from acute interstitial nephritis, which is characterized by an inflammatory infiltrate consisting of lymphocytes, eosinophils, plasma cells, and monocytes with interstitial edema or fibrosis or both.

