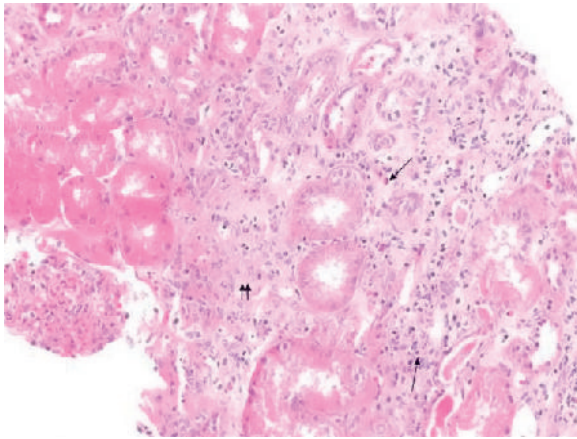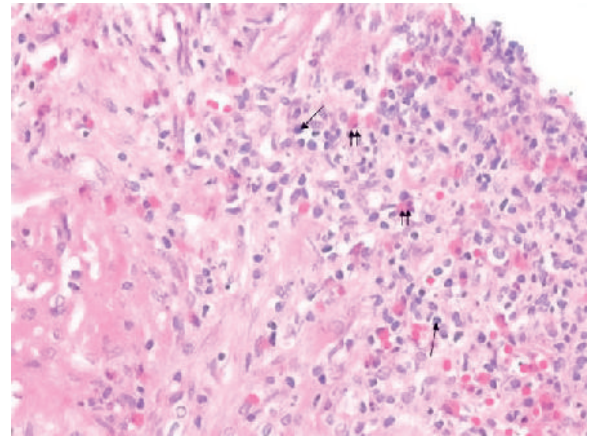


E-FIGURE 29-1 Acute interstitial nephritis. Interstitial inflammatory cell infiltrate (*arrows*) with tubular atrophy and interstitial edema (*double arrows*) (hematoxylin and eosin, $\times 200$).



E-FIGURE 29-2 Acute interstitial nephritis. Interstitial inflammatory cell infiltrate (*arrows*) with numerous eosinophils (*double arrows*) (hematoxylin and eosin, $\times 200$).

