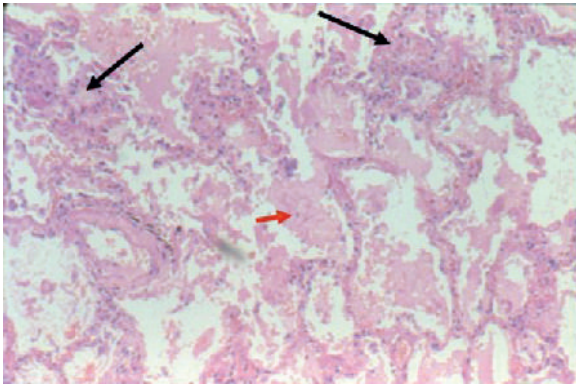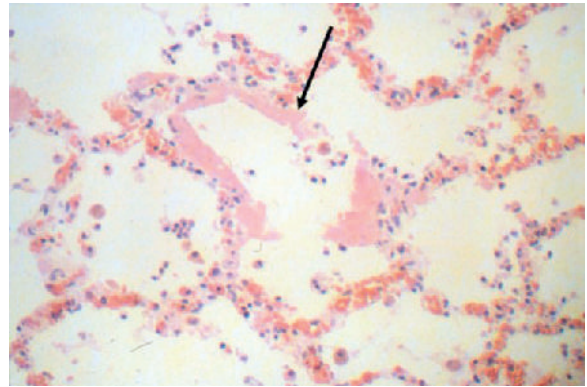

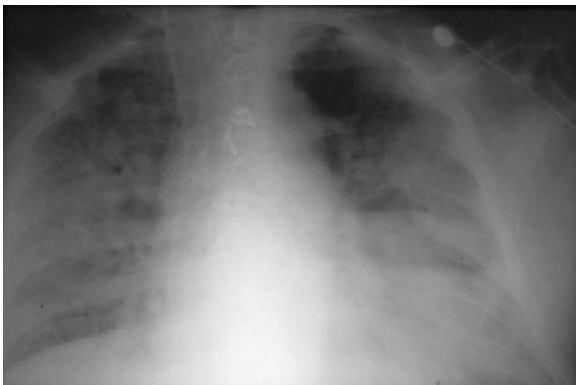
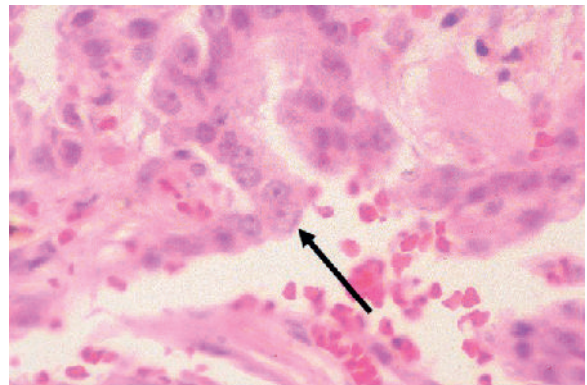
E-FIGURE 22-1 Alveolar edema and acute and chronic inflammation in acute respiratory distress syndrome.



E-FIGURE 22-3 Hyaline membranes (*arrow*), showing fibrin and other proteins.



E-FIGURE 22-2 Chest radiograph of a patient with acute respiratory distress syndrome shows diffuse alveolar infiltrates.



E-FIGURE 22-4 Type II cell hyperplasia (*arrow*) in the proliferative repair phase of acute respiratory distress syndrome.

