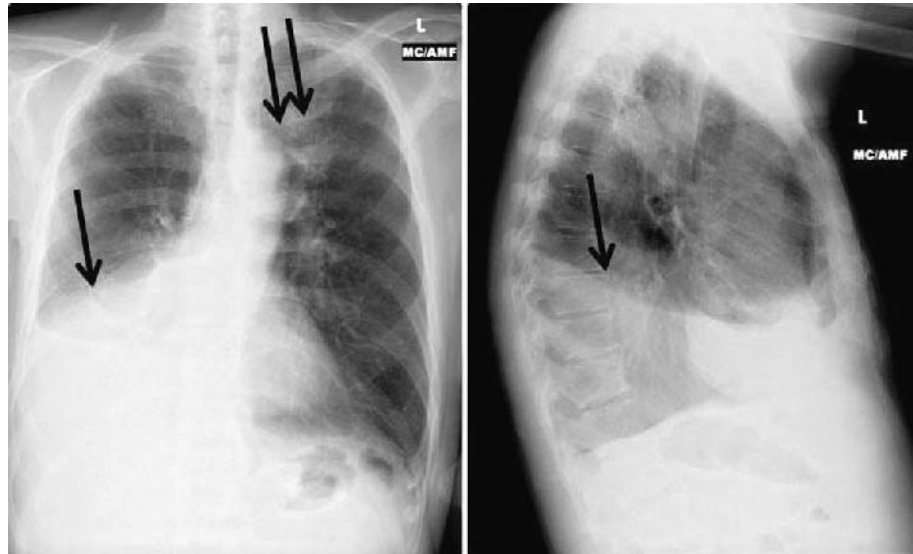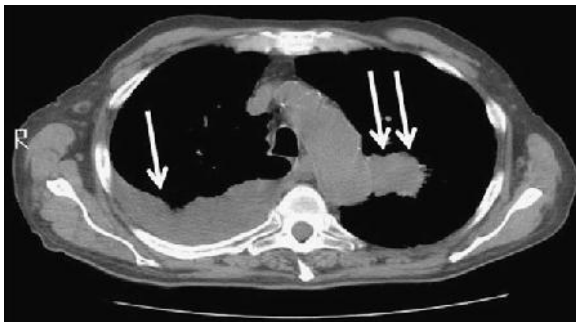
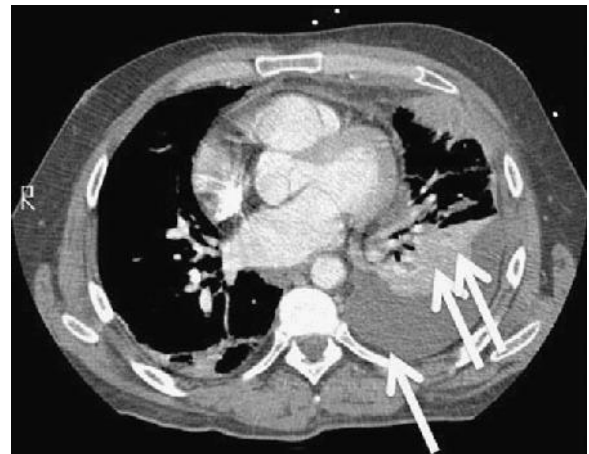


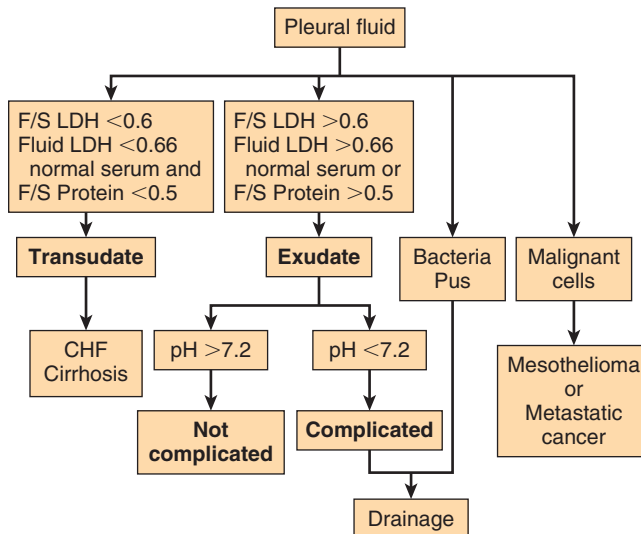
E-FIGURE 20-1 Posteroanterior and lateral chest radiographs show a large, right pleural effusion (arrow) and left upper lobe mass (double arrows).



E-FIGURE 20-2 Computed tomography of the patient in E-Figure 20-1 shows a large, right pleural effusion (arrow) and left upper lobe mass (double arrows).



E-FIGURE 20-3 Computed tomography demonstrates a pleural effusion (arrow) and atelectasis (double arrows).



E-FIGURE 20-4 Work-up for pleural effusion. CHF, Congestive heart failure; F/S, fluid/serum; LDH, lactate dehydrogenase.