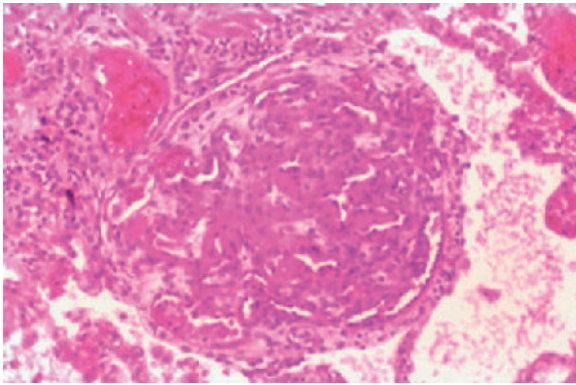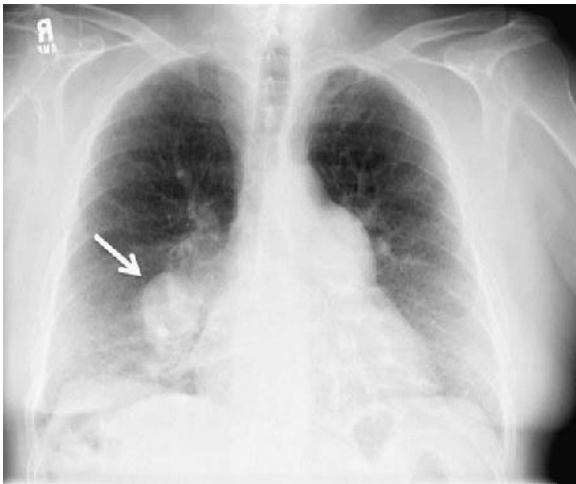
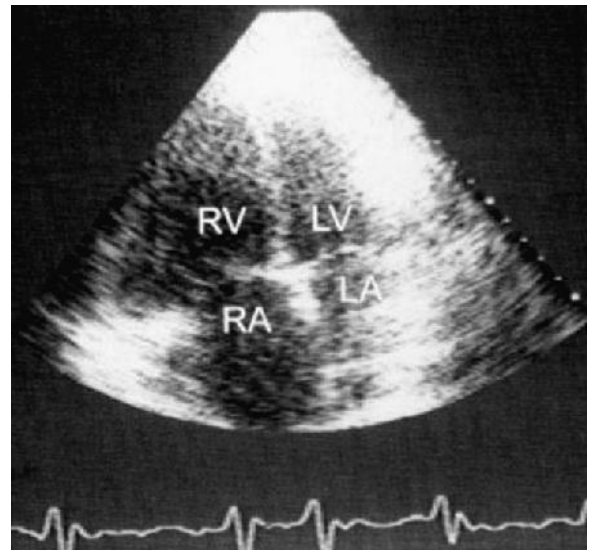


E-FIGURE 18-1 The plexiform lesion is an abnormal proliferation of pulmonary endothelial cells seen only in the setting of pulmonary arterial hypertension (hematoxylin and eosin stain). (Courtesy Dr. Charles Kuhn.)



E-FIGURE 18-2 The chest radiograph shows an enlarged right main pulmonary artery (*arrow*), which resulted from pulmonary artery hypertension.



E-FIGURE 18-3 In cases of pulmonary artery hypertension, the echocardiogram may show enlarged right atrial and right ventricular cavities. The interventricular septum is deviated to the left. LA, Left atrium; LV, left ventricle; RA, right atrium; RV, right ventricle.

