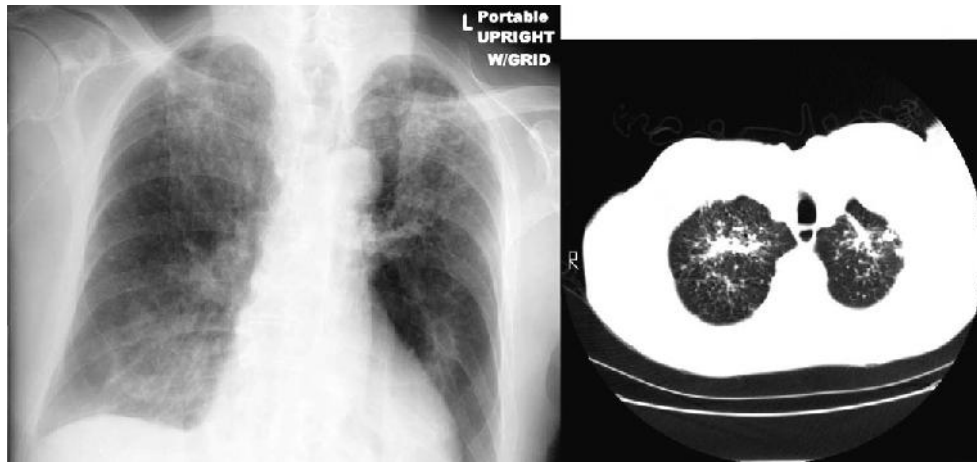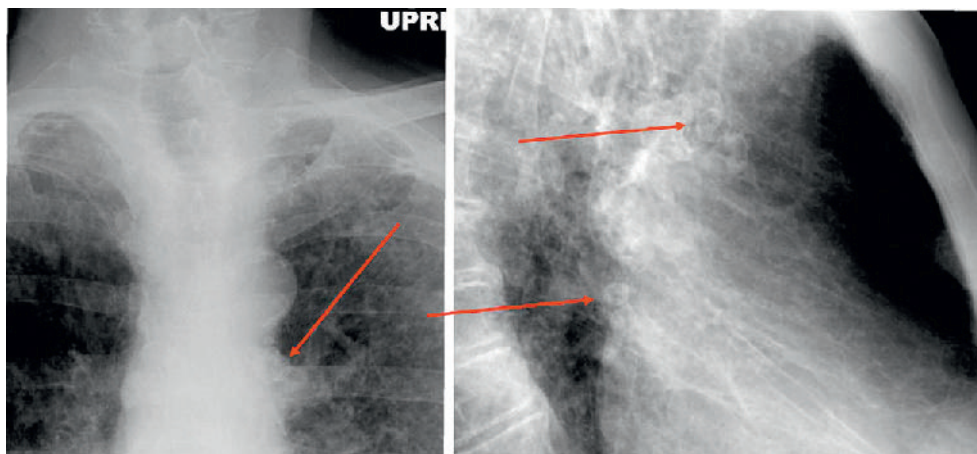




E-FIGURE 17-7 Architectural distortion of the upper lobes in a patient with silicosis.



E-FIGURE 17-8 Eggshell calcifications (*arrows*) in a patient with silicosis.