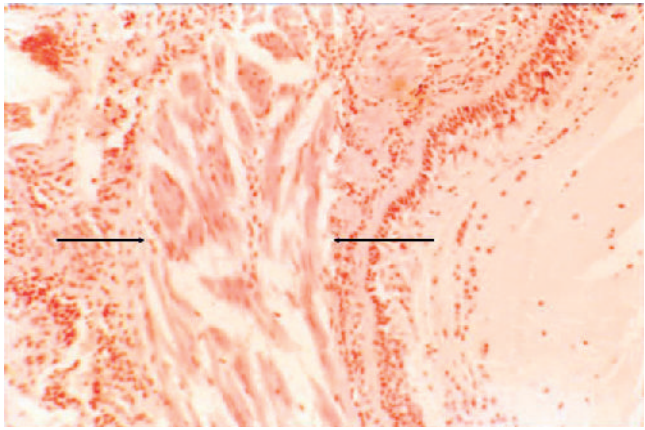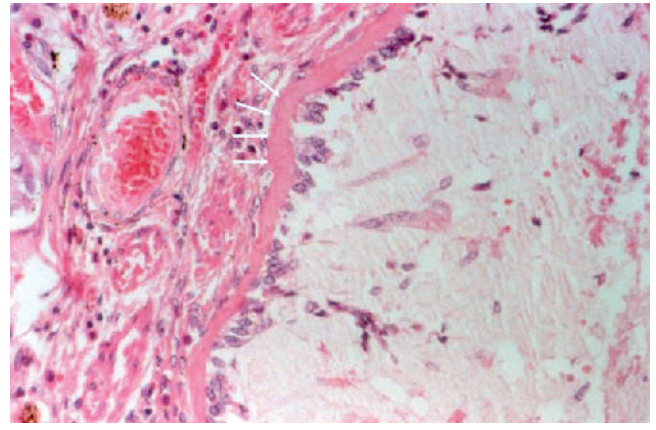


E-FIGURE 16-12 Thickening of the airway smooth muscle layer (between black arrows) in asthma. (Courtesy Dr. Charles Kuhn.)



E-FIGURE 16-13 Thickening of the subepithelial basement membrane in asthma (white arrows). (Courtesy Dr. Charles Kuhn.)

