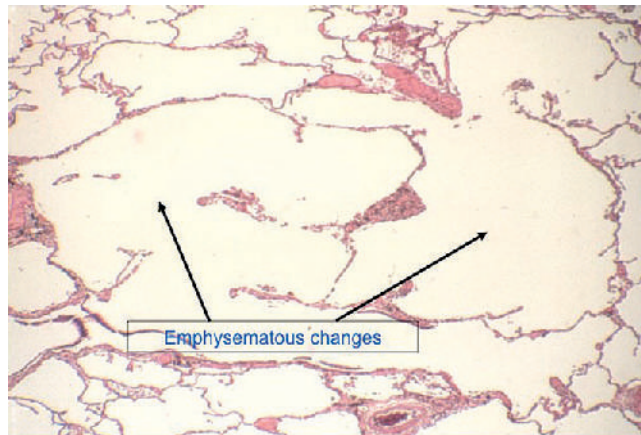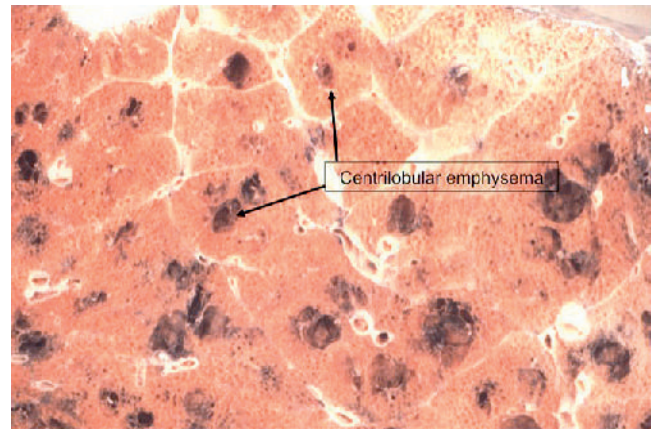
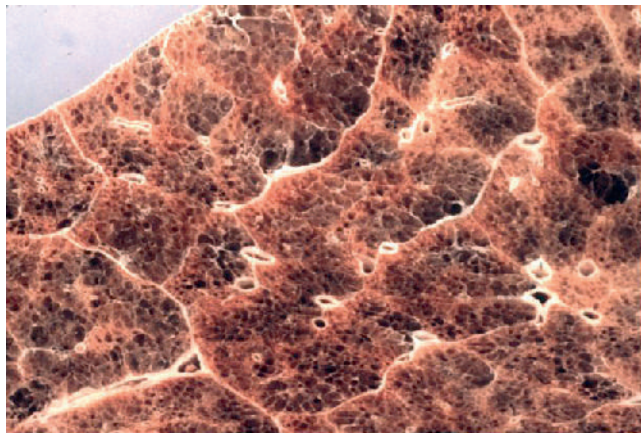


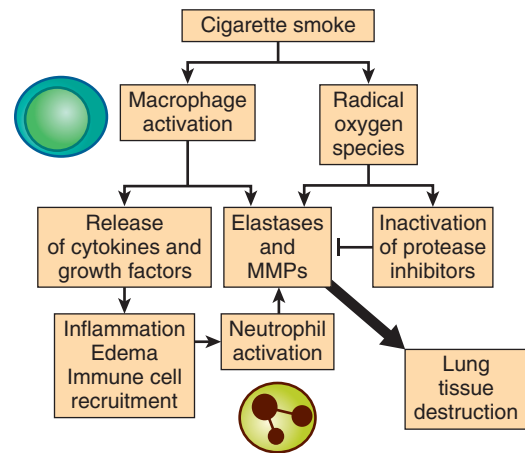
E-FIGURE 16-1 Emphysema with enlargement of distal air spaces. (Courtesy Dr. Charles Kuhn.)



E-FIGURE 16-2 Centrilobular emphysema surrounded by normal lung. (Courtesy Dr. Charles Kuhn.)



E-FIGURE 16-3 Panlobular emphysema. Emphysema extends to edge of lobules. (Courtesy Dr. Charles Kuhn.)



E-FIGURE 16-4 Mechanisms of cigarette smoke-induced inflammation and oxidant injury. MMPs, Matrix metalloproteinases.